

# Epidermoid Cyst of the Buccal Mucosa: An Uncommon Entity. Case report and literature review

nouha dammak<sup>1</sup>, abdellatif chokri<sup>1</sup>, afef slim<sup>1</sup>, Ahlem Bellalah<sup>2</sup>, Adel Bouguezzi<sup>1</sup>, sameh sioud<sup>1</sup>, hajer hentati<sup>1</sup>, and jamil selmi<sup>1</sup>

<sup>1</sup>University of Monastir Faculty of Dental Medicine of Monastir

<sup>2</sup>Fattouma Bourguiba University Hospital of Monastir

June 7, 2021

## Abstract

Epidermoid, dermoid and teratoid cysts are nonodontogenic benign lesions derived from the germinative epithelium, appearing any where of the body. In the oral cavity, these are uncommon and account for less than 0.01% of all the oral cysts. These cysts often remain asymptomatic for years however can become acutely symptomatic.

Epidermoid Cyst of the Buccal Mucosa: an Uncommon Entity.

Case report and literature review

Nouha Dammak<sup>\*1,2</sup>, Abdellatif Chokri<sup>1,2</sup>, Afef Slim<sup>1,2</sup>, Ahlem Bellalah<sup>3</sup>, Adel Bouguezzi<sup>1,2</sup>, Sameh Sioud<sup>1,2</sup>, Hajer Hentati<sup>1,2</sup>, Jamil Selmi<sup>1,2</sup>.

1.Oral Medicine, Oral Surgery Department, University Clinic of Dental Medicine, Monastir, Tunisia.

2.Oral Health and Oro-Facial Rehabilitation Laborotary (LR12ES11), Faculty of Dental Medicine, University of Monastir, Tunisia.

3.Department of pathology, Fattouma Bourguiba University Hospital of Monastir, Tunisia.

\*Corresponding Author: Nouha Dammak (dammaknouha11@gmail.com)

*Email addresses :*

Nouha Dammak :*dammaknouha11@gmail.com*

ORCID ID : <https://orcid.org/0000-0002-5184-5236>

- Abdellatif Chokri :*chokri\_abdellatif@yahoo.fr*
- Afef Slim: *afef.1604@yahoo.fr*
- Ahlem Bellalah : *ahlem.bellalah@gmail.com*
- Adel Bouguezzi: *Dr-adel@live.fr*
- Sameh Sioud :*resisam-sioud@yahoo.fr*
- Hajer Hentati :*hajer\_hentati@yahoo.fr*
- Jamil Selmi : *jamilselmimimcb@gmail.com*

*Key clinical message*

Epidermoid cyst of the buccal mucosa is rare. Nevertheless, it must be included in the differential diagnosis of swelling in this area.

The diagnosis is based on anatomopathological exam. The surgical enucleation is the gold standard of treatment.

### *Abstract*

Epidermoid, dermoid and teratoid cysts are nonodontogenic benign lesions derived from the germinative epithelium, appearing any where of the body. In the oral cavity, these are uncommon and account for less than 0.01% of all the oral cysts. These cysts often remain asymptomatic for years however can become acutely symptomatic.

*Key word* : dermoid cyst, epidermoid cyst, oral cavity, buccal mucosa.

### *Introduction*

Epidermoid, dermoid, and teratoid cysts are nonodontogenic lesions derived from the germinative epithelium [1]. These cysts can be found anywhere in the body, particularly in areas where embryonic elements fuse together [2,3]. Most of the reported cases have been localized in the ovaries, the testicles, as well as the hands and feet [2,3]. The incidence in the head and neck has been reported to be about 7% [4], with only 1.6% of cases presenting in the oral cavity [5]. The diagnosis of epidermoid cyst remains a great challenge for clinicians; as the clinical aspect is not specific and may mimic many other disease or condition. Therefore, several investigations as ultrasonography, fine needle aspiration, MRI are recommended to rule out other diagnosis [6].

The definitive diagnosis of epidermoid cyst is based on the anatomopathological exam. These cystic lesions were classified since 1955 by Meyer into epidermoid, dermoid, and teratoid variant. Dermoid cysts are lined by epidermis and contain skin adnexa such as sebaceous glands, sweat glands and hair follicles. When there are no adnexa, these cysts are termed as epidermoid or epidermal with the lining containing only epithelium. Teratoid cysts consist of dermoid material plus tissue of other embryonal sources like respiratory, gastrointestinal and connective tissues such as bundles of striated muscle and distinct areas of fat [2,3].

The epidermoid type is the most common one, comprising 85-90% of all excised cysts [7,8]. The midline or sublingual region of the mouth floor is the most commonly affected area contrary to the buccal mucosa which seems to be an unusual site of occurrence [8].

### *Case report*

A 56-year-old man in a good health was referred to the Oral Medecine and Oral Surgery department at the university clinic of dental medecine, Monastir, Tunisia, with the chief complaint of a painless swelling in the left buccal mucosa for about 5 years. The patient had neither known drug allergies, or history of surgery and/or trauma related to the lesion area.

Extraoral examination revealed the presence of a solitary swelling in the left cheek covered by normal looking skin in color and texture, as well. The swelling was nontender and freely mobile to the skin, on palpation (figure 1). No submental nor submandibular lymphadenopathy were detected.

Intraoral examination showed a poor oral hygien and a nodule in the left buccal mucosa covered by a healthy mucosa (figure 2). The mass was soft and non mobile on palpation.

Due to these clinical findings, the initial diagnosis was benign tumor of either the oral mucosa (including vascular lesions) or the salivary gland.

An ultrasonography was required. It revealed a well defined walled hyperechoic heterogenous lesion measuring 34×31×21 mm with posterior ultrasound reinforcement in the left buccal mucosa (figure 3). Vascular lesions were excluded on Colour Doppler analysis. At this stage, the diagnosis of epidermoid cyst of the left buccal mucosa was evoked.

Under local anesthesia and with intraoral access, the lesion was completely removed.

An horizontal incision in the buccal mucosa was conducted exposing a cyst immediately underlying the mucosa.

The enucleation was carefully done. Accidentally, when a partial rupture of the wall was happened, a yellow liquid was observed (figure 4).

The surgical wound was closed using a 4.0 silk suture, and the specimen was stored in 10% formol for further anatomopathological study (figure 5).

The postoperative period was uneventful and healing was good.

Histopathological examination of the surgical specimen revealed a cystic cavity. The cyst wall is composed of keratinized stratified squamous epithelium with keratin debris and no skin appendages (figure 6). This wall contains a foreign-body giant-cell reaction (figure 7).

These finding were suggestive of epidermoid cyst of the buccal mucosa.

### *Discussion*

Dermoid cyst, epidermoid cyst and teratoma are three histologically closed uncommon lesions englobed in the concept of dermoid cyst [6]. These are nonodontogenic benign lesions. Dermoid cysts are found in the head and neck region in about 7% of all cases [4]. The intraoral ones are rare and account for less than 0.01% of all the cysts [2-5]. The floor of the mouth is the most commonly affected area arising in 23% of the head and neck dermoid cyst (sublingual dermoids) [9], as this is one of the sites of embryonic fusion [4].

However, these cysts can also be found less frequently in the tongue, lips, uvula, jaw bones and buccal mucosa [3,4].

The epidermoid cysts, which were firstly described by Rose in 1859, are the most common comprising 85-90% of all excised cysts (7,8). Epidermoid cysts are also known by a number of other names, including follicular cysts, epidermal inclusion cysts and wen [2,3].

A review of the literature was conducted on the database Medline via its interface PubMed using Mesh Keywords : “oral cavity”, “cyst, epidermoid”, “cyst, dermoid” and combining the following Boolean equations : “((cyst, epidermoid[MeSH Terms]) OR (cyst, dermoid[MeSH Terms])) AND (oral cavity[MeSH Terms]) ”, until december 2020. This bibliographic research concluded to 7 case reports about epidermoid cyst of the buccal mucosa from 6 articles. The parameters extracted from these cases were summarized in Table I and concerned: gender, age, onset, site and size.

According to this literature review, the two first cases of epidermoid cyst in the buccal mucosa were published by Schneider, Mesa in 1978, and involved women in the fourth decade of their lives [10].

In the same year (1978) Gutman et al. [11] reported an atypical case of intradermal nevus which appeared to involve the wall of an epidermoid cyst. The authors believed that the cyst comprised the major portion of the lesion, and originated independently of the associated nevus.

Epidemiologically, dermoid and epidermoid cysts may be present at birth and also in old patients, with the majority occurring in the second and third decades of life [2,9]. The mean age of included patients in this review was 33 years. The present case was a 56-year-old patient which seems to be an older age than that reported in most cases.

Even though that the frequency of occurrence is equal in both genders [9], kim et al. [12] reported that male were more affected than female, which was in consistent with present case. Regarding the patients with epidermoid cysts of the buccal mucosa, including our case, 4 were male and 4 were female.

Many etiopathogenetic theories have been proposed for the development of (epi)dermoid cyst. These can be congenital or aquired [2,8]. Congenital cysts are dysembryogenetic lesions that arise from ectodermic elements, migrating into the facial midline, entrapped during the fusion of the first and second branchial arches between the 3rd and 4th weeks of intrauterine life [3,8,13]. According to the theory of acquired

development, the epidermis migrates into the deep tissue as a result of a physical trigger such as trauma or surgical complication and develops into an (epi)dermoid cyst [14]. The posttraumatic cysts are also called as implantation keratinizing epidermoid cysts [2]. Ozan et al. [3] and Rajayogeswaran et al. [13] do not believe in this congenital theory for the appearance of the lesion in the buccal mucosa. Posttraumatic cysts are usually asymptomatic and may not be associated in the patient’s mind with any specific trauma, as this may be occurred several years earlier. For the present case, the patient is not sure if an injury occurred before the appearance of the lesion.

The size of the cyst is variable from millimeters till some centimeters, depending on its first clinical manifestation [9]. This review reported that the size of epidermoid of the buccal mucosa is ranging from 10 mm to 40 mm.

There may be a left side predilection of the occurrence; as reported in the present case.

Swelling in the buccal mucosa may lead to a series of clinical diagnoses, as some conditions may present in a similar aspect making the diagnosis difficult.

The differential diagnosis of lesions occurring in the buccal mucosa with a clinical aspect similar to the present case include odontogenic infections affecting the facial spaces of buccinator and masseter muscles, pleomorphic adenoma, mucocele, cervical lymphadenopathy, hemangioma, lipoma, fibroma, neoplasms and dermoid cyst [4,8,9].

In the present case, odontogenic infection was ruled out as the lesion was not associated clinical symptoms such fever and malaise. Such the lack of nodal involvement, the slow progression of the lesion and its benign appearance, neoplastic conditions were excluded, as well.

To achieve the correct diagnosis and differentiate between vascular, salivary and mucosal lesions, specialised imaging techniques such as ultrasonography (US), computed tomography (CT), Magnetic Resonance Imaging (MRI) should be carried out [4]. On CT scans, the dermoid cyst appear as moderately thin walled, unilocular masses filled with a homogeneous, hypoattenuating fluid substance with numerous hypoattenuating fat nodules giving the pathognomonic “sack-of-marbles” appearance [4]. On MRI the lesion appears as a well-circumscribed mass. The signal intensity of epidermoid cysts is high in T2-weighted images and low in T1-weighted images. US is interesting such is a non invasive, easy, quick and cheap test. US findings revealed a well-circumscribed, smooth mass with a heterogeneous interior [4]. In the present case, the US was useful in diagnosing the lesion on the buccal mucosa. Even the aspiration biopsy is commonly used; in many cases, it can result in a not reliable diagnostic sample [9]. Thereby, imaging plays an important role, but the definitive diagnosis is based on the histopathological findings.

The surgical excision or enucleation is the gold standard treatment via an intraoral or extraoral approach, depending on the size and the location of the cysts [9]. In all cases of this review, surgeries were performed. Recently, Mumtaz et al. [15] reported the first case of dermoid cyst in the floor of the mouth being managed with marsupialization, as a good option of large epidermoid cysts.

Although recurrences have been described as less than 3% [14], these may be prevented by the complete removal of the cyst wall. There is no recurrence in all included cases.

Despite the benign nature and the good prognosis of dermoid or epidermoid cysts [4] isolated cases of premalignant and malignant conditions (Bowen’s disease, Paget’s disease, and squamous cell carcinoma) have been reported. Bhatt et al. [7] described a case of a squamous cell carcinoma that appeared in the epithelium of an epidermoid cyst in the floor of the mouth, associated with the sublingual gland.

*Table I* : Review of the literature regarding epidermoid cysts arising in the buccal mucosa.

Author	Year	Gender	Age	Onset	Site	Size
<b>Schneider (10)</b>	1978	F	36	NI	Right	10
<b>Schneider (10)</b>	1978	F	30	3 years	Left	30



Author	Year	Gender	Age	Onset	Site	Size
<b>Gutmann (11)</b>	1978	F	48	1 year	Right	15
<b>Rajayogeswaran (13)</b>	1989	M	25	1 year	Left	15*20
<b>Ozan (3)</b>	2007	F	38	6 months	Left	20*30*40
<b>Kini (2)</b>	2013	M	25	2 years	Left	15*15*15
<b>Wildsom (8)</b>	2015	M	29	4 years	Right	35
<b>Present case</b>	2020	M	56	5 years	Left	34*31*21

### *Conclusion*

Epidermoid cyst of the buccal mucosa is extremely rare. Nevertheless, it must be included in the differential diagnosis of swelling in this area. To exclude other conditions, like benign tumors and odontogenic infection, appropriate imaging techniques are necessary in preoperative.

The diagnosis is based on anatomopathological exam. The surgical enucleation is the gold standard of treatment, and usually without recurrence.

### *ACKNOWLEDGMENTS*

None.

### *CONFLICT OF INTEREST*

None.

### *AUTHOR CONTRIBUTIONS*

ND: wrote the manuscript.

AC: involved in surgery performance and manuscript revision.

AS: ensured patient follow- up and involved in manuscript drafting.

AB: analyzed and interpreted the specimen.

AB, SS, HH: involved in manuscript revision.

JS: revised the manuscript for important intellectual content.

### *Figures*

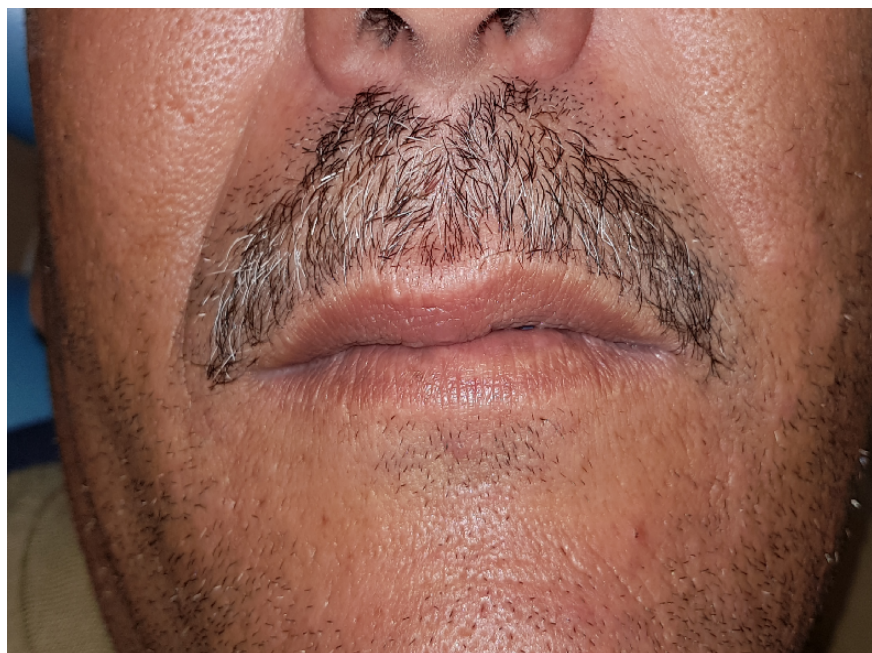

Figure1 : extra-oral view : swelling of the left cheek.

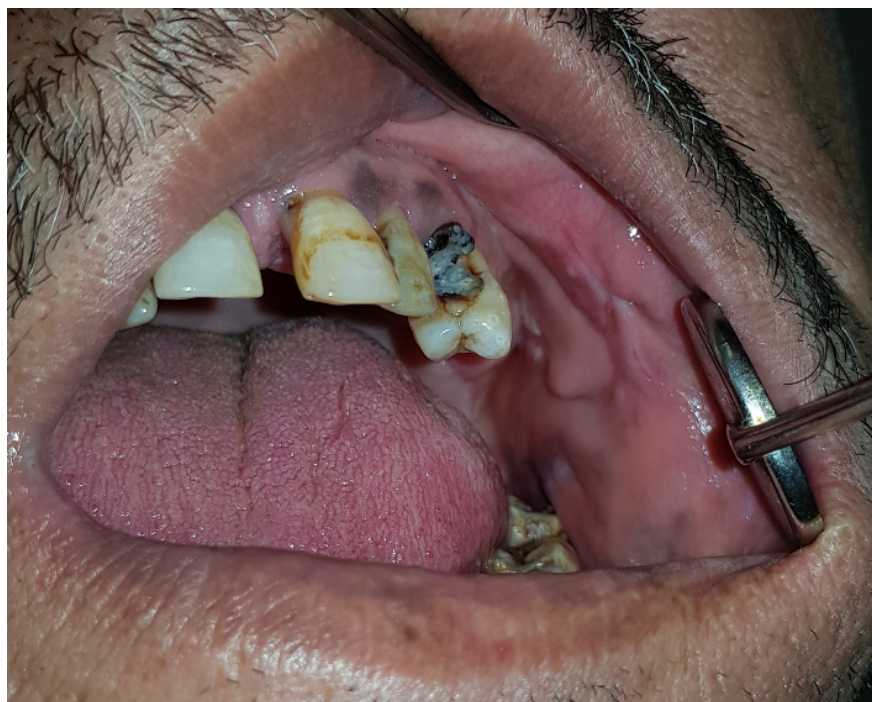

Figure 2 : intra-oral view : a nodule in the left buccal mucosa covered by a healthy mucosa.

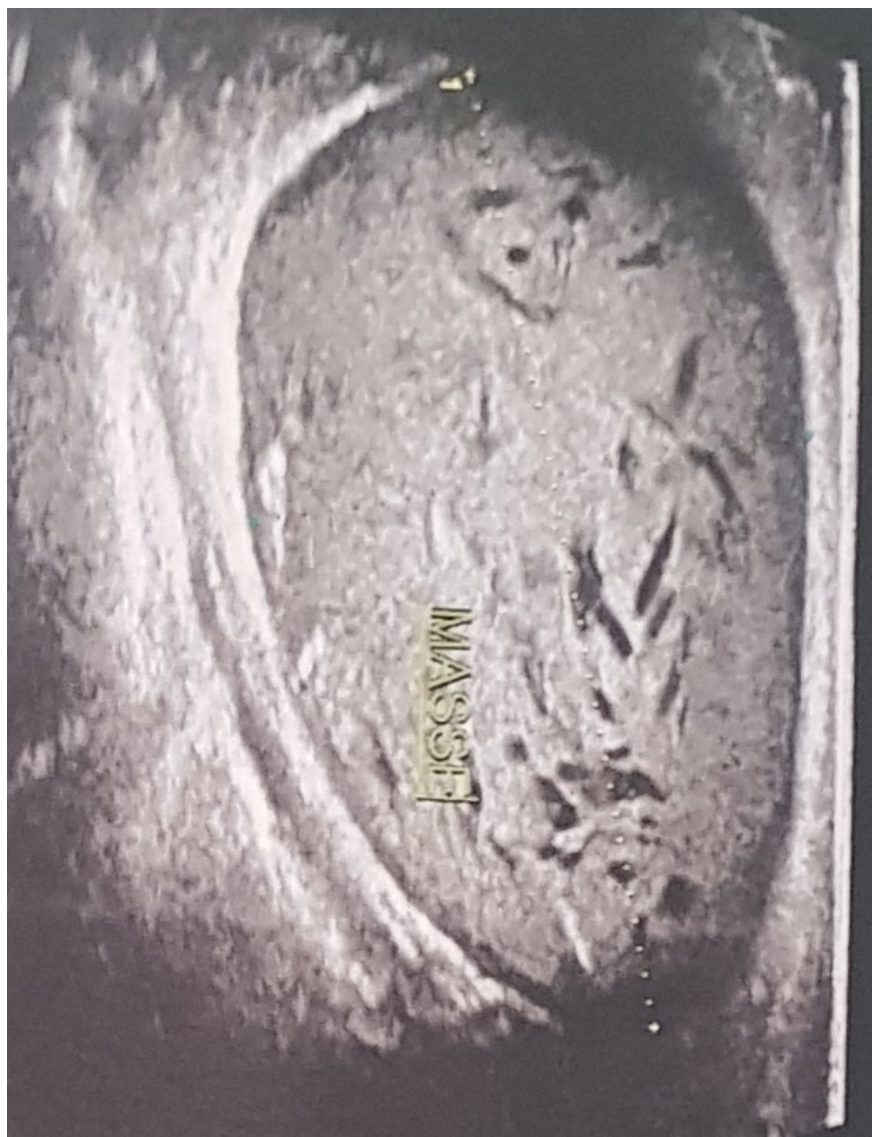


Figure 3 : echographic view : a well defined walled hyperechoic heterogenous lesion measuring  $34 \times 31 \times 21$  mm with posterior ultrasound reinforcement in the left buccal mucosa region.

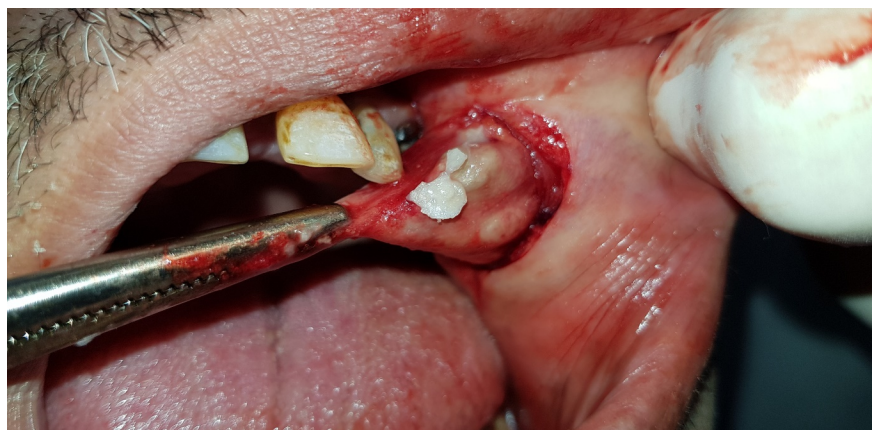

Figure 4 : peroperative view : cyst enucleation and the yellow colour of the intra cystic liquid.

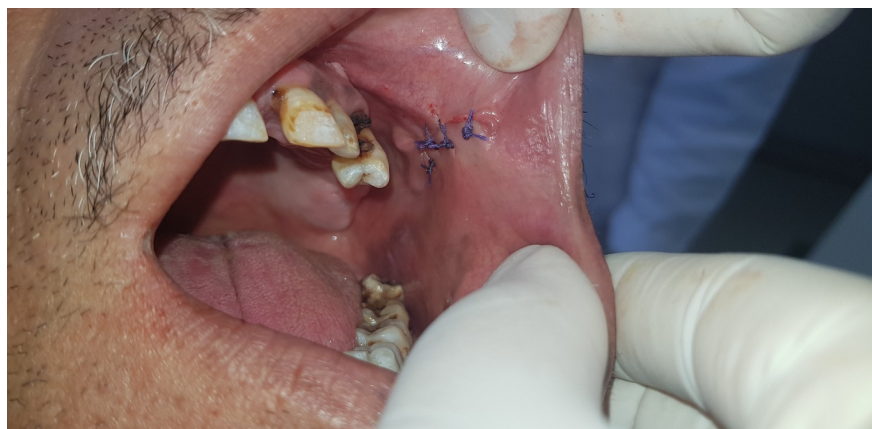

Figure 5 : postoperative view.



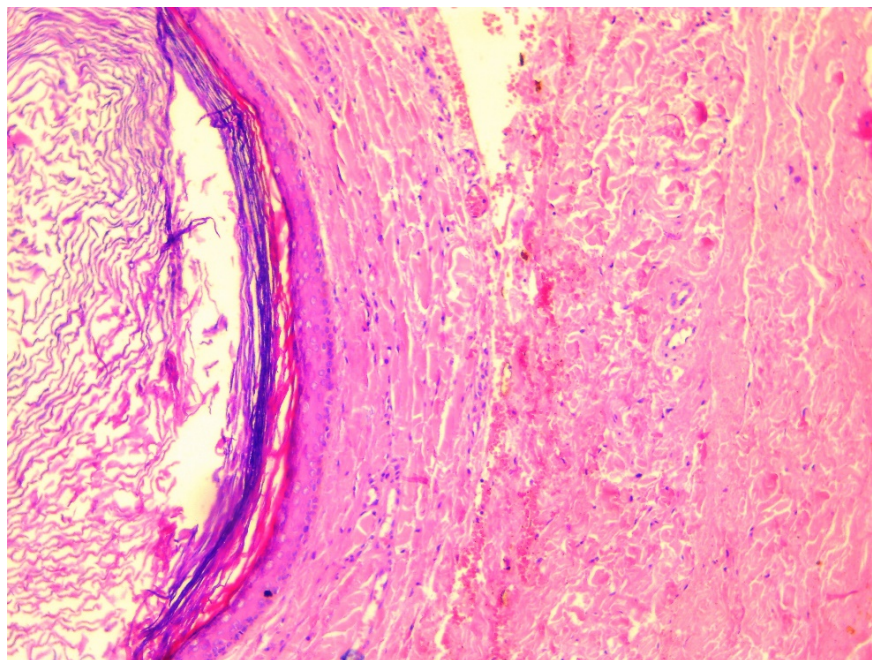


Figure 6 : The cyst wall is composed of keratinized stratified squamous epithelium with keratin debris and no skin appendages.

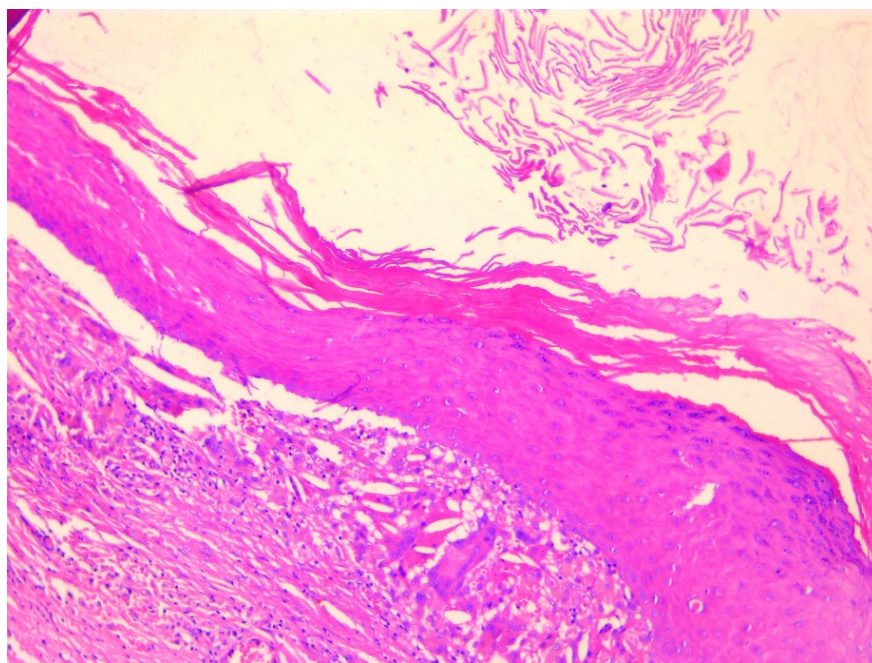


Figure 7 : The cyst wall contains a foreign-body giant-cell reaction.

### *References*

1. Rastogi V, Puri N, Kaur G, Yadav L, Sharma R. Unusual Cases of Epidermoid cyst: Case Series.

2013;01(02):5.

2. Kini YK, Kharkar VR, Rudagi BM, Kalburge JV. An Unusual Occurrence of Epidermoid Cyst in the Buccal Mucosa: A Case Report with Review of Literature. *J Maxillofac Oral Surg.* 2013 Mar;12(1):90–3.
3. Ozan F, Polat HB, Ay S, Goze F. Epidermoid Cyst of the Buccal Mucosa: A Case Report. *J Contemp Dent Pract.* 2007 Mar;8(3):90–6.
4. Sahoo NK, Choudhary AK, Srinivas V, Kapil Tomar. Dermoid cysts of maxillofacial region. *Med J Armed Forces India.* 2015 Dec;71:S389–94.
5. Santos Hb, Rolim Ls, Barros Cc, Cavalcante Il, Freitas Rd, Souza Lb. Dermoid and epidermoid cysts of the oral cavity: a 48-year retrospective study with focus on clinical and morphological features and review of main topics. *Med Oral Patol Oral Cirurgia Bucal.* 2020;e364–9.
6. Brunet-Garcia A, Lucena-Rivero E, Brunet-Garcia L, Faubel-Serra M. Cystic mass of the floor of the mouth. *J Clin Exp Dent.* 2018;0–0.
7. Bhatt V, Evans M, Malins TJ. Squamous cell carcinoma arising in the lining of an epidermoid cyst within the sublingual gland – a case report. *Br J Oral Maxillofac Surg.* 2008 Dec;46(8):683–5.
8. Wildson Gurgel Costa F, Samuel Rodrigues Carvalho F, Chaves FN, de Almeida S, Negreiros Nunes Alves AP, do Socorro Vidal Patrocínio RM, et al. Epidermoid Cyst Arising in the Buccal Mucosa: Case Report and Literature Review. *Acta Stomatol Croat.* 2015 Mar 15;49(1):65–73.
9. Vieira EMM, Borges AH, Volpato LER, Porto AN, Carvalhosa AA, Botelho G de A, et al. Unusual Dermoid Cyst in Oral Cavity. *Case Rep Pathol.* 2014;2014:1–3.
10. Schneider LC, Mesa ML. Epidermoid cysts of the buccal mucosa. *Q Natl Dent Assoc Inc.* 1978 Jan;36(2):39–42.
11. Gutmann J, Cifuentes C, Gandulfo P, Guesalaga F. Intradermal nevus associated with epidermoid cyst in the mucous membrane of the cheek. *Oral Surg Oral Med Oral Pathol.* 1978 Jan;45(1):76–82.
12. Kim JP, Lee DK, Moon JH, Park JJ, Woo SH. Transoral Dermoid Cyst Excision: A Multicenter Prospective Observational Study. *Otolaryngol Neck Surg.* 2018 Dec;159(6):981–6.
13. Rajayogeswaran V, Eveson JW. Epidermoid cyst of the buccal mucosa. *Oral Surg Oral Med Oral Pathol.* 1989 Feb;67(2):181–4.
14. Montebugnoli L, Gissi DB, Marchetti C, Foschini MP. Multiple squamous cell carcinomas of the oral cavity in a young patient with graft-versus-host disease following allogeneic bone marrow transplantation. *Int J Oral Maxillofac Surg.* 2011 May;40(5):556–8.
15. Mumtaz S, Singh M. Transoral Marsupialization of a Large Dermoid Cyst. *J Oral Maxillofac Surg.* 2019 Apr;77(4):753–6.