

HSV Encephalitis: An atypical presentation of delirium

Nicholas Ming Hao Wan¹ and Sanath Weerakkody¹

¹Flinders Medical Centre

January 7, 2023

Abstract

Herpes Simplex Encephalitis is the most common cause of infectious encephalitis. Our case is of a 75-year-old woman who presented with dysuria and altered mental status. Our case addresses the difficulties in diagnosis and highlights the importance of early recognition of HSE and its associated neurological sequelae.

Hosted file

Case Report HSV Encephalitis.docx available at <https://authorea.com/users/573627/articles/617817-hsv-encephalitis-an-atypical-presentation-of-delirium>

Figure 1

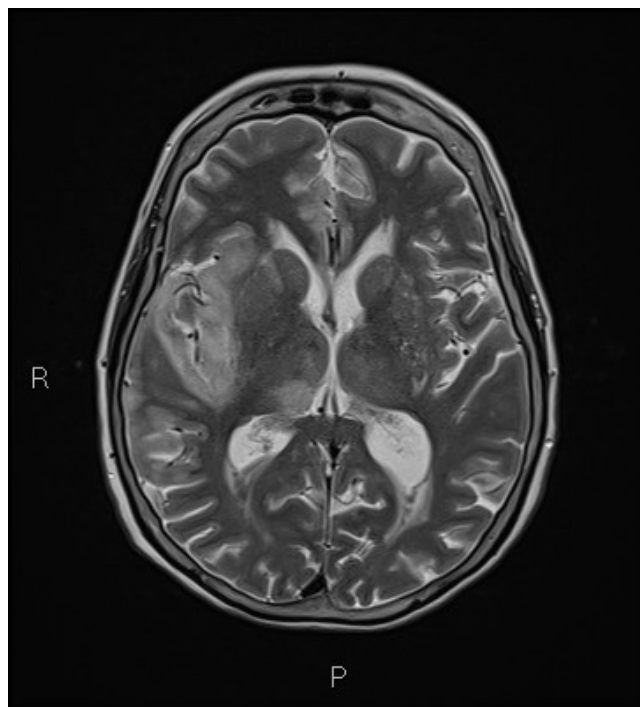


Fig. 1 Magnetic Resonance Imaging (MRI) demonstrating generalized oedematous changes of the right temporal lobe with moderate intensity restricted diffusion seen involving the gyri of the right temporal lobe and right insular regions.