Posted on 10 Jan 2023 — The copyright holder is the author/funder. All rights reserved. No reuse without permission. — https://doi.org/10.22541/au.167335747.70304108/v1 — This a preprint and has not been peer reviewed. Data may be preliminary.

Fatal Disseminated Adenovirus Disease in a Patient who Received Chemotherapy for Mantle Cell Lymphoma: A Case Report

Bo Yu[1], Lakshmi Saravanan [2], Dena Tran[3], Alexander Davies[4], Harpreet Kaur[5], Shivakumar Narayanan[5], Avelino Verceles[5], and Hyeong Kim[5]

[1]University of Maryland Medical Center Midtown Campus
[2]American University of Antigua College of Medicine
[3]University of Maryland Medical Center
[4]University of Maryland School of Medicine
[5]UMMC Midtown Campus

January 10, 2023

Abstract

Disseminated adenovirus infections in patients who received chemotherapy alone for lymphoma are extremely rare, however, should be included in differential diagnosis for those who received T cell suppressive agents. We report a fatal case of disseminated adenovirus disease in a patient who had received chemotherapy and presented with hypoxia

Fatal Disseminated Adenovirus Disease in a Patient who Received Chemotherapy for Mantle Cell Lymphoma: A Case Report

Bo Yu, MD[1], Lakshmi Saravanan, BSc[2], Dena H. Tran, MD[1], Alexander J. Davies, MD[3], Harpreet Kaur, MD[4], Shivakumar Naraynanan, MBBS[4], Avelino C. Verceles, MD, MS[3], Hyeong J. Kim, MD[3]

[1]Department of Medicine, University of Maryland Medical Center Midtown Campus, 827 Linden Avenue, Baltimore, MD 21201, USA.

[2]American University of Antigua College of Medicine, Jabberwock Road, Osbourn, Antigua and Barbuda.

[3]Division of Pulmonary and Critical Care Medicine, 22 S Greene Street, Baltimore, MD 21201, USA.

[4]Department of Infectious Diseases, University of Maryland Medical Center Midtown Campus, 827 Linden Avenue, Baltimore, MD 21201, USA.

Corresponding Author:

Bo Yu, MD

Department of Medicine

University of Maryland Medical Center Midtown Campus

827 Linden Avenue

Baltimore, MD 21201, USA

Email: mailto:mdyu321@hotmail.com

Abstract

Posted on 10 Jan 2023 — The copyright holder is the author/funder. All rights reserved. No reuse without permission. — https://doi.org/10.22541/au.167335747.70304108/v1 — This a preprint and has not been peer reviewed. Data may be preliminary.

Background: Adenovirus (ADV) may cause severe complications in hematopoietic stem cell transplant recipients, but disseminated ADV infections in patients who received chemotherapy alone for hematological malignancies are poorly understood due to the rarity of cases. Despite being diagnostically challenging, a more specific workup needs to be initiated with a low threshold in patients who are exposed to agents with the potential to suppress T cells. We report a fatal case of disseminated ADV disease in a patient with mantle cell lymphoma who had received combination chemotherapy and presented with hypoxia.

Case Description: A 75-year-old man who was diagnosed with Mantle cell lymphoma 10 months prior was admitted for mild hypoxic respiratory failure. Bendamustine, Rituximab, Cytarabine regimen had resulted in complete remission, with the last cycle of chemotherapy being 3 months prior to admission. CT of the chest revealed ground-glass opacities concerning pneumonia. Initial laboratory tests were remarkable for mild leukopenia. The Respiratory Viral Panel was only positive for ADV. He did not respond to empiric antibiotics for community- acquired pneumonia and Trimethoprim / Sulfamethoxazole later on in light of positive Beta D Glucan concerning for Pneumocystis pneumonia. Then, he developed hemorrhagic cystitis, followed by liver and renal function derangement which prompted checking serum ADV Polymerase Chain Reaction (PCR). This test took 1 week to return, showing a viral load of 50, 000 copies/ml, suggesting disseminated ADV infection. Despite treatment with Cidofovir, the multi-organ failure progressed, and the follow-up viral load had doubled on day 20. The patient passed away the same day.

Conclusions:

Disseminated ADV infection in patients who only received chemotherapy is a very rare phenomenon. T cell suppression seems to be a risk factor for disseminated disease. Clinicians may need to maintain a low threshold to send serum quantitative ADV PCR when symptoms are not improved by anti-microbial treatment for more conventional infections in patients who received agents that are known to suppress T cells, such as Bendamustine.

Keywords: adenovirus infection, chemotherapy, Bendamustine, Cidifovir, Case Report

Background

Human adenovirus infection can cause a wide spectrum of diseases in the immunocompetent host that is generally mild and self-limiting. However, in immunocompromised hosts, adenovirus infection can be severe with progression to multisystem organ failure resulting in mortality as high as 55% [1]. Disseminated Adenovirus infection(DAI) can involve the respiratory tract, gastrointestinal genitourinary systems, myocardium, central nervous system, and eyes [2]. There is a wide estimate for the incidence of adenovirus infection following hematopoietic stem cell transplants, ranging from 5-20% [3,4]. The immune response to adenovirus is T-cell mediated and allogeneic transplant recipients are at the highest risk of severe disease, however, disseminated disease in adult patients with underlying hematologic malignancy who have not received stem cell transplant seems rare. We report a fatal case of disseminated Adenovirus infection in an immunocompromised patient with mantle cell lymphoma who had received combination chemotherapy and Rituximab but had not undergone stem-cell transplantation.

Case Presentation

A 75-year-old man presented to our emergency room with cough and worsening dyspnea on exertion for the previous four days. His medical history was significant for mantle cell lymphoma diagnosed 10 months prior to admission, for which he received six cycles of Bendamustine, Rituximab, Cytarabine (BRCA) followed by maintenance Rituximab. He completed chemotherapy 3 months before this admission, and his last dose of Rituximab was 6 weeks prior. He had achieved a complete metabolic response based on recent PET(Positive Electron Tomogtaphy) imaging and blood work. On arrival to the emergency room, he was hypoxic requiring supplemental oxygen via nasal cannula, but otherwise appeared well. Heart and lung auscultation normal. Computed Tomography Angiography (CTA) chest revealed widespread patchy ground-glass opacities bilaterally compatible with multifocal pneumonia (Figure 1). Laboratory results revealed white blood cell count 3.2 K/mcL with 60% neutrophils, 20% bands, and 6% lymphocytes. Lactate dehydrogenase was elevated

1959 units/L(normal range 313-618 u/L), ferritin 1622 ng/ml(normal range 17.9-464.0 ng/ml), D-Dimer 1670 ng/ml(normal range <749ng/ml). Nasopharyngeal swab for SARS-COV2 polymerase chain reaction (PCR) was negative.

Figure 1. Representative slices of CT chest obtained on hospital day 1 showed patchy ground-glass opacity with areas of increased consolidation, especially in the left lower lobe.

Urine antigen assay for *Streptococcus pneumoniae* and*Legionella pneumophila* were negative. Given his immunocompromised state, opportunistic pathogens including*Pneumocystis jirovecii*(PJP), and other fungal causes of infectious pneumonia were considered, and beta-d-glucan testing was sent. Drug-related hypersensitivity pneumonitis or lung injury due to Rituximab were also considered but felt less likely given the timing of presentation. The nasopharyngeal swab was positive for Adenovirus by multiplex polymerase chain reaction by multiplex respiratory virus PCR panel. He was started on empiric antibiotic therapy with ceftriaxone and azithromycin for possible superimposed community-acquired pneumonia and admitted to the medical ward for ongoing care.

On hospital day 4 his hypoxemia worsened. He was transitioned to high flow nasal cannula, initiated on dexamethasone based on dosing per RECOVERY trial [5] for potential viral induced Acute Respiratory Distress Syndrome (ARDS), and he was admitted to the intensive care unit. At the time of upgrading to ICU level of care, the patient's Beta-D-Glucan test resulted positive, and considering the CT chest findings and worsening hypoxemic respiratory failure, Trimethoprim-Sulfamethoxazole was initiated for high suspicion of PJP pneumonia. Bronchoscopic sampling was not obtained for antigen confirmation due to tenuous respiratory status.

On hospital day 5 patient developed hematuria, initially mild and thought to be due to traumatic foley catheter insertion, but gradually increasing in quantity to the point of requiring continuous bladder irrigation. Urinalysis with culture and ultrasound of urinary tract were obtained without evidence of obstruction/calculi, or bacterial urinary tract infection, raising concern for hemorrhagic cystitis. This first suggestion of disseminated adenoviral infection prompted serum adenoviral PCR testing to be sent. On hospital day 7, transaminases were noted to be elevated with ALT 203 U/L and AST 176 U/L. The patient concurrently developed declining renal function with creatinine rising to 1.5 mg/dL (baseline creatinine 0.9mg/dL) in the context of stable hemodynamics and a negative viral hepatitis panel. The constellation of findings of interstitial pneumonia, transaminitis, and gross hematuria with acute kidney injury further supported a diagnosis of disseminated adenovirus infection. Dexamethasone was therefore held, and the patient was given intravenous immunoglobulin based on limited data [6,7]. He was not given Cidofovir however due to worsening renal injury.

The patient completed a 5-day course of ceftriaxone and vancomycin for presumed superimposed bacterial pneumonia and was kept on trimethoprim/sulfamethoxazole for possible PJP pneumonia as this differential diagnosis could not be safely ruled out during the course of his hospitalization. Over the next week patient's clinical status continued to slowly decline, with the need for increasing levels of supplemental oxygen via high flow system (Figure 2), worsening renal failure necessitating renal replacement therapy, and increasing abdominal distension with adynamic ileus on imaging. On hospital day 12, whole blood adenovirus polymerase chain reaction (PCR) that had been sent seven days earlier returned positive, yielding a load of 548,000 copies/ml. Diagnosis of disseminated Adenovirus infection was therefore confirmed. Repeat chest imaging at this time showed progression of multifocal ground-glass opacities and evidence of organization and early fibrotic changes (Figure 3). Despite the renal failure, the decision was made it start the patient on Cidofovir therapy at 3mg/kg, dosing twice weekly, in conjunction with probenecid. Additionally, given progressively worsening hypoxemic respiratory failure despite maximum medical therapy including continuous renal replacement therapy and escalation to BiPAP patient was resumed on dexamethasone as salvage therapy.

Unfortunately, over the following days patient's mentation declined likely due to Central nervous system(CNS) involvement of infection (CNS imaging was not obtained based on goals of care discussion) and

Posted on 10 Jan 2023 — The copyright holder is the author/funder. All rights reserved. No reuse without permission. — https://doi.org/10.22541/au.167335747.70304108/v1 — This a preprint and has not been peer reviewed. Data may be preliminary.

he was transitioned to full comfort measures, passing away on hospital day 18. Repeat adenovirus PCR sent shortly before patients died revealed a viral load further increased to greater than 10,000,000 copies/ml (>7 log copies).

The timeline of this case is illustrated in figure 4.

Figure 2. Daily progression of supplemental oxygen requirements.

Figure 3. Representative slices of CT chest obtained on hospital day 12 showed more diffuse ground-glass opacities with peripheral clearing and reticulations consistent with organization and early fibrotic changes.

Figure 4. Timeline of clinical findings, treatment, and course

Discussion and Conclusion

Adenovirus is a common pathogen associated with upper and lower respiratory tract infections, as well as viral conjunctivitis. The viral infection is usually self-limiting, although devastating disseminated infections in immunocompetent individuals have been reported [8]. Disseminated Adenovirus infection usually occurs in immunocompromised hosts, such as those who underwent hematopoietic stem cell transplant (HSCT), solid organ transplant(SOT), or patients with acquired immunodeficiency syndrome (AIDS). Disseminated disease can manifest in the form of interstitial pneumonia, hepatitis, meningoencephalitis, and tubulointerstitial nephritis.

The incidence of adenovirus infection in patients who underwent HSCT can be highly variable (3-47%) [9,10] and disease is usually limited to one organ system (gastrointestinal, genitourinary, or respiratory system), and disseminated disease is considered if involving two organs or more, but not including adenovirus viremia [1,11]. Based on hemagglutination traits, Adenovirus species are divided into A-G groups. Disseminated diseases in HSCT recipients appeared to be more caused by Adenovirus C species [12,13]. In SOT recipients, adenovirus infection is frequently allograft limited, though disseminated diseases are not uncommon [14].

Conditioning chemotherapy before the HSCT is known to cause long-lasting effects on the host's immune system due to depletion of host T/B cells leading to increased risks of opportunistic infections. The reconstitution of immunity with engraftment is also a complicated and high-risk process related to the development of severe infections. T-cell depletion by alemtuzumab or anti-thymocyte globulin is known to increase the risk of disseminated Adenovirus [15].

However, there are limited data about adenovirus infection in non-HSCT/SOT patients who received only chemotherapy for hematological malignancies. Bendamustine has the features of both alkylating and antimetabolite chemotherapy agents. Due to its presumed safe side effect profiles, Bendamustine is often used off-label to treat indolent lymphomas, such as follicular lymphoma and chronic lymphocytic leukemia. More recent data suggest Bendamustine can cause significant and prolonged CD4+ suppression of 24-26 months in a high percentage of patients who received it either as 1st line therapy or advanced treatment line [16], leading to increased risk for both community-acquired and opportunistic infections including adenovirus infection when compared to other chemotherapy agents for the treatment of indolent non-Hodgkin Lymphoma in elderly patients [17].

Rituximab is associated with increased risks of hepatitis B, Varicella zoster virus, and Cytomegalovirus infections [18]. In comparison, there is only one case of Rituximab-related fulminant adenoviral hepatitis reported, who received 11200 mg total dose of Rituximab for his lymphoma [19]. Our patient's chemotherapy regimen consisted of Bendamustine, Cytarabine, and Rituximab (total dose of 3700mg) and he did have lymphocytopenia at presentation though specific T/B cell subsets were not measured by flow cytometry that would be valuable to provide more granular measurements of the adaptive immunity.

Of note, multiplex tools have limited sensitivity in general since they are designed to only detect common Adenovirus serotypes. Though being questioned about its value in the general patient population, it may still serve as a quick and convenient diagnostic modality in the diagnosis of possible opportunistic infections in immunocompromised patients as in our case. In the context of clinically severe disease, physicians may

Posted on 10 Jan 2023 — The copyright holder is the author/funder. All rights reserved. No reuse without permission. — https://doi.org/10.22541/au.167335747.70304108/v1 — This a preprint and has not been peer reviewed. Data may be preliminary.

favor the management of more common infectious processes while diagnostic cues are weighted for multiple possibilities. In our case, the patient had two positive Beta-D-glucan tests and relevant CT chest findings pointing to the better-recognized PCP pneumonia.

Currently, there is no U.S. Food and Drug Administration (FDA)-approved medicine for disseminated Adenovirus disease. Nonetheless, Cidofovir is the standard treatment for disseminated Adenovirus in many centers, but dosing regimens are center-specific. There is no current study that compares the safety and efficacy of the two most frequently used regimens: 5 mg/kg every 12-2 weeks and 1 mg three times per week. Although a low-dose regimen was associated with less nephrotoxicity, this may carry a higher risk of treatment failure and breakthrough infection [20]. Besides, Cidofovir has unpredictable effects as some patients seemed to respond well while others did not. BrinCidofovir is a lipid ester of Cidofovir with less nephrotoxicity than Cidofovir, which was reported to have a higher intracellular level important for virustatic effect. A few case reports showed the success of BrinCidofovir in the treatment of refractory Adenovirus infection thus it may be a promising drug of choice in the future, but more data are needed to confirm its efficacy. At this point, the availability of BrinCidofovir is also limited by the lack of approval by the FDA or its counterparts. Adoptive transfer of donor Adenovirus specific T-cells (ACT) is an experimental therapy with prompt response in HSCT, but this intervention failed to show the same benefits in solid organ transplant recipients [21]. For patients deemed to receive chemotherapy as the only treatment for hematological malignancies, it is also unrealistic to routinely isolate and expand Adenovirus specific T-cells from each patient due to the low incidence of disseminated Adenovirus infections in general.

To conclude, disseminated adenovirus infections in patients with hematological malignancies who have not undergone stem cell transplantation are rarely reported. Diagnosis of disseminated adenovirus infection(DAI) remains very challenging and given limited treatment options with unclear efficacy, early identification so that targeted therapies can be given in a timely manner may be key to ensuring good outcomes. Suspicion for DAI should be raised when interstitial pneumonia, hemorrhagic cystitis, acute liver injury, and other organ specific manifestations are present without an obvious cause, especially in the setting of a positive nasal PCR test for adenovirus. DAI should be especially suspected in patients who received agents that can severely suppress T cell population, such as Bendamustine, Alemtuzumab, and Antithymocyte immune globulin. Cidofovir is currently the standard treatment for severe adenovirus infection, though the ideal regimen is unclear. Its derivative medication, BrinCidofovir, may offer better efficacy at less risk of nephrotoxicity, however, more data is required.

List of abbreviations

ACT: Adenovirus specific T-cells

ADV: adenovirus

AIDS: Acquired immunodeficiency syndrome

ALT: alanine aminotransferase

ARDS: Acute Respiratory Distress Syndrome

AST: aspartate aminotransferase

BRCA: bendamustine, rituximab, cytarabine

CNS: Central nervous system

CT: Computed Tomography

CTA: Computed Tomography Angiography

FDA: Food and Drug Administration

HSCT: hematopoietic stem cell transplant

Posted on 10 Jan 2023 — The copyright holder is the author/funder. All rights reserved. No reuse without permission. — https://doi.org/10.22541/au.167335747.70304108/v1 — This a preprint and has not been peer reviewed. Data may be preliminary.

PCP: Pneumocystis jirovecii

PCR: Polymerase Chain Reaction

PET: Positive Electron Tomography

SOT: solid organ transplant

References

1. Echavarría M. Adenoviruses in immunocompromised hosts. *Clin Microbiol Rev* . 2008;21(4):704-15.
2. Lion T. Adenovirus infections in immunocompetent and immunocompromised patients. *Clin Microbiol Rev* . 2014;27(3):441-62.
3. Chakrabarti S, Mautner V, Osman H, et al. Adenovirus infections following allogeneic stem cell transplantation: incidence and outcome in relation to graft manipulation, immunosuppression, and immune recovery. *Blood* . 2002;100(5):1619-27.
4. Humar A, Kumar D, Mazzulli T, et al. A surveillance study of adenovirus infection in adult solid organ transplant recipients.*Am J Transplant* . 2005;5(10):2555-9.
5. RECOVERY Collaborative Group; Horby P, Lim WS, Emberson JR, et al. Dexamethasone in Hospitalized Patients with Covid-19. *N Engl J Med* . 2021;384(8):693-704.
6. Sofer A, Arger N, Vest M. Successful Treatment of Adenovirus-Induced ARDS With Cidofovir and IVIG. *CHEST* . 2013;144(4):229A. doi:10.1378/chest.1699502.
7. Permpalung N, Mahoney MV, Alonso CD. Adjunctive Use of Cidofovir and Intravenous Immunoglobulin to Treat Invasive Adenoviral Disease in Solid Organ Transplant Recipients. *Pharmacotherapy* . 2018;38(12):1260-1266.
8. Lynch JP 3rd, Kajon AE. Adenovirus: Epidemiology, Global Spread of Novel Serotypes, and Advances in Treatment and Prevention. *Semin Respir Crit Care Med.* 2016;37(4):586-602.
9. Ison MG. Adenovirus infections in transplant recipients. *Clin Infect Dis* . 2006;43(3): 331-9.
10. Symeonidis N, Jakubowski A, Pierre-Louis S, et al. Invasive adenoviral infections in T-cell-depleted allogeneic hematopoietic stem cell transplantation: high mortality in the era of Cidofovir. *Transpl Infect Dis* . 2007;9(2):108-13.
11. Bordigoni P, Carret AS, Venard V, et al. Treatment of adenovirus infections in patients undergoing allogeneic hematopoietic stem cell transplantation. *Clin Infect Dis.* 2001;32(9): 1290-7.
12. Lion T, Kosulin K, Landlinger C, et al. Monitoring of adenovirus load in stool by real-time PCR permits early detection of impending invasive infection in patients after allogeneic stem cell transplantation. *Leukemia.* 2010;24(4): 706-14.
13. Qurashi YMAA, Guiver M, Cooper RJ. Sequence typing of adenovirus from samples from hematological stem cell transplant recipients. *J Med Virol* . 2011;83(11):1951-8.
14. Florescu DF, Schaenman JM, AST Infectious Diseases Community of Practice. Adenovirus in solid organ transplant recipients: Guidelines from the American Society of Transplantation Infectious Diseases Community of Practice. *Clin Transplant.* 2019;33(9):e13527.
15. Joffe M, Wagner SD, Tang JW. Case report: a fatal case of disseminated adenovirus infection in a non-transplant adult hematology patient.*BMC Infect Dis.* 2018;18(1):58.
16. Saito H, Maruyama D, Maeshima AM, et al. Prolonged lymphocytopenia after Bendamustine therapy in patients with relapsed or refractory indolent B-cell and mantle cell lymphoma. *Blood Cancer J* . 2015;5(10):e362.
17. Fung M, Jacobsen E, Freedman A, et al. Increased risk of infectious complications in older patients with indolent Non-Hodgkin Lymphoma exposed to Bendamustine. *Clin Infect Dis.* 2019;68(2):247-255.
18. Kelesidis T, Daikos G, Boumpas D, et al. Does Rituximab increase the incidence of infectious complications? A narrative review. *Int J Infect Dis* . 2011;15(1):e2-16.
19. Iyer A, Mathur R, Deepak BV, et al. Fatal adenoviral hepatitis after Rituximab therapy. *Arch Pathol Lab Med* . 2006;130(10):1557-1560.
20. Anderson EJ, Guzman-Cottrill JA, Kletzel M, et al. High-risk adenovirus-infected pediatric allogeneic hematopoietic progenitor cell transplant recipients and preemptive Cidofovir therapy. *Pediatr Trans-*

Posted on 10 Jan 2023 — The copyright holder is the author/funder. All rights reserved. No reuse without permission. — https://doi.org/10.22541/au.167335747.70304108/v1 — This a preprint and has not been peer reviewed. Data may be preliminary.

plant . 2008;12(2):219-27.
21. Feucht J, Opherk K, Lang P, et al. Adoptive T-cell therapy with hexon-specific Th1 cells as a treatment of refractory adenovirus infection after HSCT. *Blood.* 2015;125(12):1986-94.

Declarations:

Ethics approval and consent to participate

Not Applicable

Consent for publication

Written consent to publish this case report and any accompanying images was obtained from the patient's next of kin.

Availability of data and materials

Any data (suitably anonymized to maintain patient confidentiality) is available for readers to review if a suitable written request to the Corresponding author is made.

Competing interests

All authors declare that they have no competing interests.

Funding

University of Maryland Health Sciences and Human Services Library's Open Access Publishing Fund

Authors Contributions

BY, DT, AV, HK(Hyeong Kim) – participated in the direct care of the patient in the ICU. SN and HK(Harpreet Kaur)– Infectious Disease consultant, also helped with forming the discussion part of this paper. BY and LS – wrote the initial draft, which was edited for style and accuracy by DT, AV, SN, and AD. All authors critically reviewed the manuscript for publication. All authors have read and approved the final version of this manuscript.

Acknowledgements

None

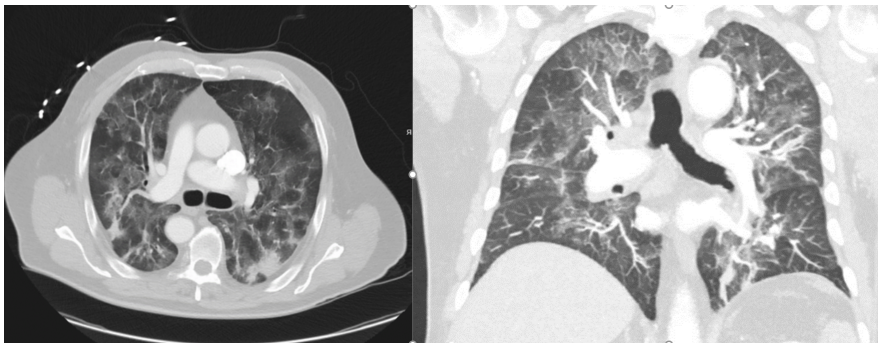

10/01	10/02	10/03	10/04	10/05	10/06	10/07	10/08	10/09	10/10	10/11	10/12	10/13	10/14	10/15	10/16	10/17	10/18	
0701	0701	0701	0701	0701	0701	0701	0701	0701	0701	0701	0701	0701	0701	0701	0701	0701	0701	
Nasal ...	Non-re...	High f...	High f...	High f...	High f...	High f...	High f...	High f...	High f...	High f...	High f...	High f...	High f...	High f...	Bi-PAP	Bi-PAP	Bi-PAP	Oxygen Device
		60	70	70	45	80	60	60	60	60	70	60	60	65	60	80	80	FiO2
5	15	35	35	35	40	40	40	50	50	60	60	60	60	60	70	45		Flow Rate

Posted on 10 Jan 2023 — The copyright holder is the author/funder. All rights reserved. No reuse without permission. — https://doi.org/10.22541/au.167335747.70304108/v1 — This a preprint and has not been peer reviewed. Data may be preliminary.
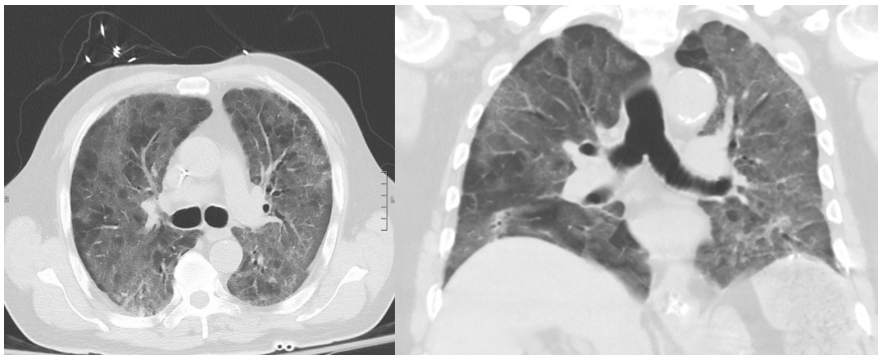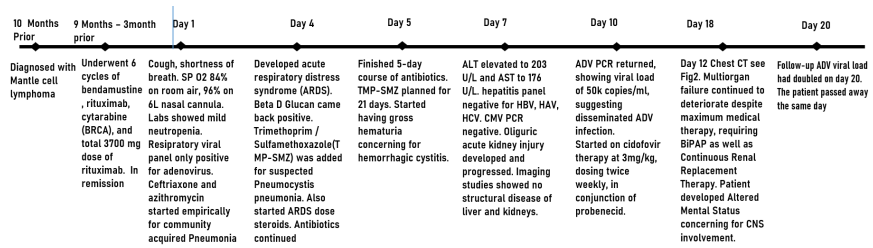
Posted on 10 Jan 2023 — The copyright holder is the author/funder. All rights reserved. No reuse without permission. — https://doi.org/10.22541/au.167335747.70304108/v1 — This a preprint and has not been peer reviewed. Data may be preliminary.