

A Case of Non-Ischemic Cardiomyopathy

Frank Annie¹, Fatima Ahmed², Ahmad Elashery², Sarah Rinehart², and Muhammad Amer²

¹Affiliation not available

²CAMC Department of Cardiology, Area Medical Center, Charleston Area Medical Center, and Charleston Area Medical Center Research Institute and Center for Clinical Sciences Research, Research Scientist CAMC Health Education and Research Institute

January 18, 2023

A Case of Non-Ischemic Cardiomyopathy

Frank H Annie, PhD¹, Fatima Ahmed, MD², Ahmad Elashery, MD², Sarah Rinehart, MD²,
Muhammad Amer, MD²

¹ Charleston Area Medical Center Institute for Academic Medicine
3200 MacCorkle Ave. SE, Charleston, WV 25304.

²CAMC Department of Cardiology, Charleston Area Medical Center.
3200 MacCorkle Ave SE, Charleston, WV 25304

Study Locations:

Charleston Area Medical Center, 3100 McCorkle Ave SE, Charleston, WV, 25302 and
Charleston Area Medical Center Research Institute and Center for Clinical Sciences Research,
3200 McCorkle Ave SE, Charleston, WV, 25302

Correspondence:

Frank Annie M.A; MPA, PhD
Research Scientist
CAMC Health Education and Research Institute
3200 MacCorkle Ave. SE,
Charleston, WV 25304
Phone 304-388-9921
Fax: 304-388-9921
Email: Frank.H.Annie@camc.org

Total word count: 499

Author Disclosure Block: None

Key words: Cardiomyopathy, LMNA

Running Title: Non-Ischemic Cardiomyopathy

Total Number of Tables and Figures: 4

Potential Conflicts: None

Case Presentation:

A 25-year-old Caucasian landscaper with no significant past cardiovascular history, presented with recurrent sudden onset palpitations and blurred vision for few weeks. Family history was strongly positive for congestive heart failure.

Physical examination was rather unremarkable. A 12 lead EKG showed sinus rhythm, short PR interval (<120 ms), and a right bundle branch block (Figure 1). Laboratory work-up hs-troponin at 25 pg/mL (normal= <20) with minimal delta. Transthoracic echocardiogram findings were significant for mildly dilated, severely diffuse hypokinetic Left Ventricle with an EF of 20-25% and grade III diastolic dysfunction with elevated left atrial pressure, mild-moderate mitral and tricuspid valve regurgitation. Coronary CTA did not show coronary artery disease or anomaly. A cardiac MRI showed a LVEF of 38%, and RVEF of 30%, with no evidence of prior infarction or late gadolinium enhancement. He was sent home with maximum tolerable guideline-directed medical therapy for CHF and Wearable Cardiac Defibrillator.

Genetic panel for cardiomyopathy revealed heterozygosity for the LMNA gene mutation, supporting highly suspected diagnosis of Lamin A/C cardiomyopathy. He was found to have recurrent non-sustained VT on WCD (Figure 2-4). He did not have any syncopal events nor received shocks from wearable cardiac defibrillator. He received an AICD for primary prevention while genetic cascade testing for biologic family members being followed.

Discussion:

The prevalence of non-ischemic cardiomyopathy is estimated at 1/500 to 1/250 individuals (1). It predominantly affects younger individuals, while genetic correlations can be identified in about 40% of cases (2). Lamin A/C gene, is one of the most thoroughly investigated cardiomyopathy-related genes, which is associated with a higher incidence of Ventricular Arrhythmias or Sudden Cardiac death (SCD). Some studies suggest that the rate of SCD in Lamin A/C gene mutation carriers is as high as 46% (3, 4). In a retrospective study of 49 families of patients with dilated cardiomyopathy in Colorado, USA, and Italy, 12 carriers of the LMNA mutation were identified in younger patients (age of onset 27+/-5 years) compared to without the mutation, and their phenotype was frequently associated with electrophysiological abnormalities, such as supraventricular arrhythmias and conduction disease. Compared to non-carriers, carriers of the LMNA mutation were 2.6 times more likely to suffer cardiovascular death, 3.4 times more likely to experience cardiovascular death or transplant, and 2.2 times more likely to have cardiovascular death, transplant, or major event (5). European Society of Cardiology recommends consideration for an cardioverter defibrillator in patients with dilated cardiomyopathy and a confirmed disease-causing LMNA mutation with clinical risk factors [NSVT during ambulatory electrocardiogram monitoring, LVEF <45% at first evaluation, male sex and non-missense mutations (insertion, deletion, truncations or mutations affecting splicing)] (6).

Conclusion:

In younger patients with a strong family history of heart failure and early death, with minimal suspicion for drug-induced or infiltrative cardiomyopathies, genetic testing aids in the accurate

diagnosis, and guides for timely interventions for life saving therapies such as cardiac defibrillator.

There is no need for 90 day waiting for such patients as despite improvement in EF, life threatening

VA's are common with LMNA mutations.

References

1. McKenna WJ, Maron BJ, Thiene G. Classification, epidemiology, and global burden of cardiomyopathies. **Circ Res**. 2017; *121*:722–730.
2. Hershberger RE, Hedges DJ, Morales A. Dilated cardiomyopathy: the complexity of a diverse genetic architecture. **Nat Rev Cardiol**. 2013; *10*:531–547. .
3. Kumar S, Baldinger SH, Gandjbakhch E, Maury P, Sellal JM, Androulakis AF, Waintraub X, Charron P, Rollin A, Richard P, Stevenson WG, Macintyre CJ, Ho CY, Thompson T, Vohra JK, et al. Long-term arrhythmic and nonarrhythmic outcomes of Lamin A/C mutation carriers. **J Am Coll Cardiol**. 2016; *68*:2299–307.
4. van Berlo JH, de Voogt WG, van der Kooi AJ, van Tintelen JP, Bonne G, Yaou RB, Duboc D, Rossenbacker T, Heidebuchel H, de Visser M, Crijns HJ, Pinto YM. Meta-analysis of clinical characteristics of 299 carriers of LMNA gene mutations: do Lamin a/C mutations portend a high risk of sudden death? **J Mol Med (Berl)**. 2005; *83*:79–83.
5. Taylor MR, Fain PR, Sinagra G et al. Natural history of dilated cardiomyopathy due to lamin A/C gene mutations. **J Am Coll Cardiol**. 2003; *41* (5):771–780
6. Priori SG, Blomström-Lundqvist C, Mazzanti A, et al. ESC Scientific Document Group, 2015 ESC Guidelines for the management of patients with ventricular arrhythmias and the prevention of sudden cardiac death: The Task Force for the Management of Patients with Ventricular Arrhythmias and the Prevention of Sudden Cardiac Death of the European Society of Cardiology (ESC) Endorsed by: Association for European Paediatric and Congenital Cardiology (AEPC), **Eur Heart J**. 2015; *36* (41):2793–2867

Figure Legend:

Figure 1. Base line ECG (NSR, Short PR interval and RBBB with repolarization changes), Wide complex tachycardia on Wearable Cardiac Defibrillator, Cardiac MRI showing short axis images showing no late gadolinium enhancement, Cross-Section of images.

Figure 2: Pedigree Tree – Of the last 3 generations

Figure 1:

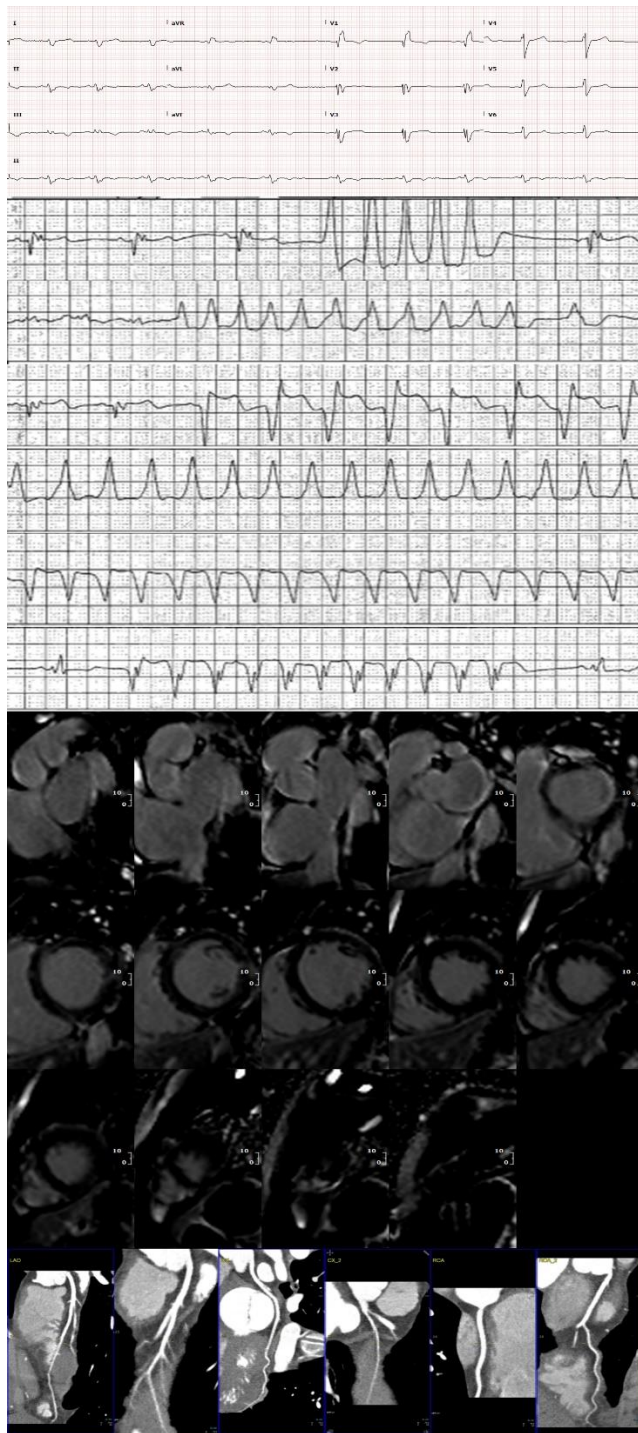


Figure 2:

