Posted on 9 May 2023 — The copyright holder is the author/funder. All rights reserved. No reuse without permission. — https://doi.org/10.22541/au.168363934.41978978/v1 — This a preprint and has not been peer reviewed. Data may be preliminary.

Thrombus or Tumor ?

Shiho Wakasa[1], Hiroya Hayashi[1], Takanori Yamazaki[1], Yasuhiro Izumiya[1], and Daiju Fukuda[1]

[1]Osaka Metropolitan University Graduate School of Medicine

May 9, 2023

Abstract

Our patient was a 61-year-old man with dedifferentiated chondrosarcoma (DCS) and a benign thrombus or a tumor thrombus. We diagnosed the patient with a tumor thrombus by angioscopic observation of a smooth-surfaced, white, elevated lesion in the IVC that had invaded the vein wall. Although anticoagulant therapy was discontinued, his condition progressed without an elevation in D-dimer levels or the appearance of new thromboembolism. After one course of chemotherapy, the patient refused to continue the treatment and was treated with palliative care. He died of the underlying disease approximately half a year later. This is the first case of a DCS patient where benign and tumor thrombi was differentiated by angioscopy. Angioscopy is one of the useful tools for this differentiation which can evaluate the color tone and surface properties of an object.

Main Text

A 61-year-old Japanese man had dedifferentiated chondrosarcoma (DCS) arising in the right femur. Preoperative contrast-enhanced computed tomography (CT) revealed a contrast defect in the right femoral vein (*Figure A*). We suspected that either a benign thrombus or a tumor thrombus had developed involving the inferior vena cava (IVC) and placed a temporary IVC filter (Neuhaus Protect, Toray Medical, Tokyo, Japan) in the perioperative period and he underwent femoral tumor removal. Twenty days after the operation, contrast-enhanced CT showed extension of the contrast defect from the right popliteal vein to IVC and new pulmonary embolic findings in the right pulmonary artery (*Figure B, C*). We started him on anticoagulation therapy with rivaroxaban 15 mg/day, which did not reduce the contrast defect or the pulmonary embolism. We placed the IVC Filter (Denali, Bard Peripheral Vascular, Inc., Tempe, AZ) and observed the lesion with angioscope (Visible, Intertec Medical, Tokyo, Japan). We diagnosed the patient with a tumor thrombus by angioscopic observation of a smooth-surfaced, white, elevated lesion in the IVC that had invaded the vein wall (*Figure D, Video*).

Previous reports have demonstrated that FDG-PET and T2-weighted MRI can distinguish benign and tumor thrombi [12]. However, clinically, it is not always easy to distinguish between the two. Angioscopy facilitates these distinctions because it visually evaluates. Our report has the potential to serve as a new diagnostic method for tumor thrombus in the future.

References

1. Sharma P, Kumar R, Jeph S, et al. 2011. 18F-FDG PET-CT in the diagnosis of tumor thrombus: can it be differentiated from benign thrombus? *Nucl Med Commun* . 32(9):782-788.

2. Yedururi S, Chawla S, Amini B, et al. 2018. Tumor thrombus in the large veins draining primary pelvic osteosarcoma on cross sectional imaging. *Eur J Radiol* . 105:49-55.

Legends

Figure. Contrast-enhanced computed Tomography showing images and angioscopic image of the tumor thrombus.

1. A contrast defect image in the right femoral vein.
2. A conrastt defect image in the inferior vena cava.
3. A new pulmonary embolism in right A10.
4. The surface was smooth with white solid components.
5. The boundary between the wall of the inferior vena cava and the tumor component.

Supplementary file.

Video. Angioscopic video of the tumor thrombus.

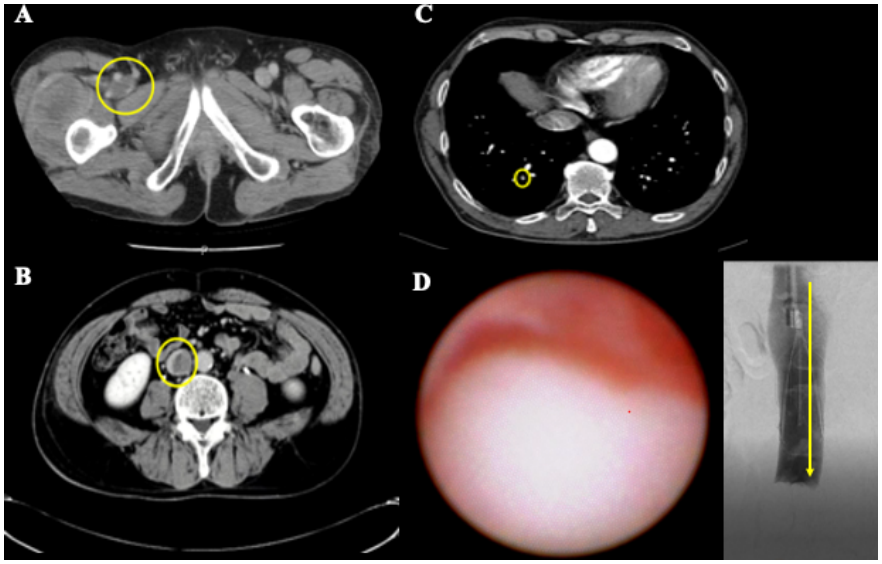

Posted on 9 May 2023 — The copyright holder is the author/funder. All rights reserved. No reuse without permission. — https://doi.org/10.22541/au.168363934.41978978/v1 — This a preprint and has not been peer reviewed. Data may be preliminary.