

A Case of Takayasu Arteritis in a Young Female: Clinical Features, Diagnostic Challenges, and Treatment Approach.

Anubhav Poudel¹, Eliz Achhami¹, Seshkanta Lamichhane², Mira Khatun³, and Bidur Khatiwada⁴

¹Sukraraj Tropical and Infectious Disease Hospital

²Bir Hospital

³Government of Nepal Ministry of Health and Population

⁴Nepalese Army Institute of Health Sciences

July 14, 2023

Title Page:-

“A Case of Takayasu Arteritis in a Young Female: Clinical Features, Diagnostic Challenges, and Treatment Approach”

Anubhav Poudel¹, Eliz Achhami², Seshkanta lamichhane³, Mira Khatun⁴, Bidur Khatiwda⁵

¹Sukraraj Tropical & Infectious Disease Hospital, Kathmandu, Nepal

(email:- poudelanubhav93@gmail.com)

² Sukraraj Tropical & Infectious Disease Hospital, Kathmandu, Nepal

(email:- eliz0917@gmail.com)

³ Bir Hospital, Kathmandu, Nepal

(email:- lamichhaneak1312@gmail.com)

⁴ Bangeshal Health Post, Pyuthan, Nepal

(email:- mirak5107@gmail.com)

⁵Nepalese Army Institute of Health Sciences, Kathmandu, Nepal

(email:- drbidurkhatiwada@gmail.com)

*Corresponding author.

Eliz Achhami, MBBS

Sukraraj Tropical & Infectious Disease Hospital, Kathmandu, Nepal

Mobile no. : - 977-9846710319

E-mail: eliz0917@gmail.com

ACKNOWLEDGMENT:-

We would like to acknowledge the patient herself and her relatives who allowed us to share their clinical report to the global platform, so that others will be benefitted.

CONFLICT OF INTEREST:-

The authors would like to declare that they have no competing interests.

A FUNDING STATEMENT:-

No funding was generated for this case report

AUTHORS CONTRIBUTION:-

1. Anubhav Poudel :- design of study, data collection, evidence collection, involved in patient management, manuscript writing and revision.
2. Eliz Achhami : design of study, data collection, evidence collection, manuscript writing and revision, involved in patient management, corresponding author.
3. Seshkanta lamichhane: involved in patient management, data collection, design of study, manuscript writing and revision.
4. Mira Khatun:- design of study, data collection, involved in patient management, manuscript revision
5. Bidur Khatiwda: - design of study, data collection, manuscript revision.

ETHICAL APPROVAL:-

As case reports are exempt from ethical approval in our institution, our article which describes a case report does not require additional permissions from the Ethics committee.

CONSENT:-

Full written informed consent was obtained from the patient for publication of her case, clinical images, and radiographic images. A copy of written consent can be made available to the editor in chief of this journal upon request.

DATA AVAILABILITY S TATEMENT:-

All the data generated or analyzed during this study are included in the manuscript.

Introduction:-

Takayasu arteritis (TA), which was first described in 1908, is now acknowledged as an inflammatory disease of unknown origin that primarily affects the aorta and its main branches, pulmonary arteries, and coronary arteries in young females¹. The disease is characterized by inflammatory infiltrates involving all layers of the arteries, including acute exudative inflammation and chronic granulomatous inflammation primarily located in the media and adventitia along with hyperplasia and neovascularization of the intimal layer². The wide range of clinical presentations associated with Takayasu arteritis makes its diagnosis challenging. This case study aims to illustrate the clinical features, diagnostic assessment, and treatment approach for Takayasu arteritis in a 22-year-old female presenting with neurological symptoms.

Case presentation:-

A 22-year-old female presented to the outpatient department with complaints of persistent headaches, vision problems, recurrent dizziness, and easy fatigability. She reported that her headaches worsened in crowded areas during the daytime and were accompanied by nausea. These symptoms had been ongoing for the past year. She had previously undergone ophthalmologic evaluation and was prescribed glasses and eye drops. Additionally, the patient had experienced episodes of dizziness, leading to falls while performing daily tasks, such as working in a hot oven or buying vegetables. Despite investigations, no abnormal findings were detected, and the patient was unable to provide any available test reports. Over time, she noticed a gradual decline in her vision specifically during exertion, which improved after rest and head bending. Walking or engaging in activities would induce dizziness, requiring her to take frequent breaks.

Her undiagnosed illness had a negative impact on her mental health, resulting in decreased sleep, feelings of worthlessness, hopelessness, and guilt. She was subsequently diagnosed with depression. In a fit of anger

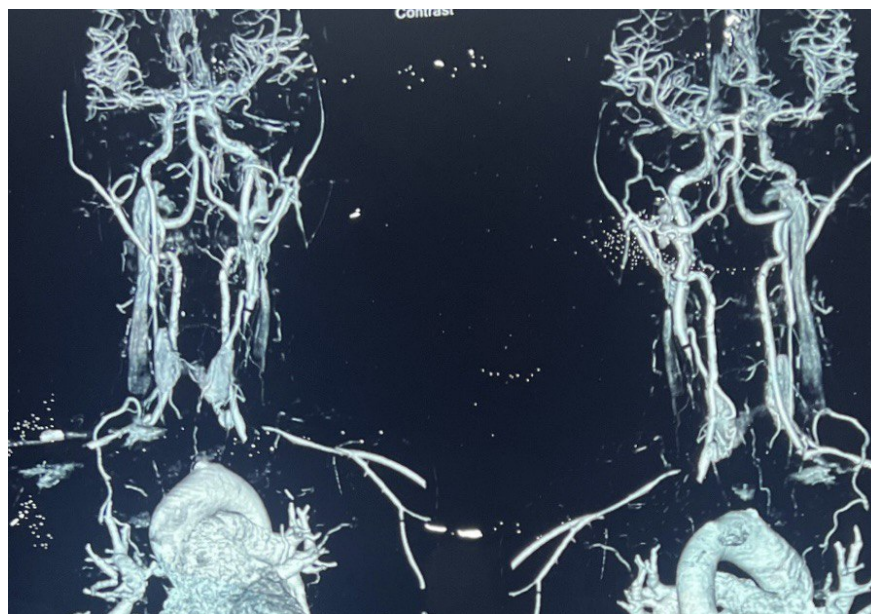
and rage, the patient described an episode of unconscious self-harm where she cut her left wrist. Although she was promptly taken to a nearby hospital, there was no evidence of bleeding at the site of the cut. She received three months of medication for her depression, which significantly improved her symptoms. A healed scar remained visible on her left wrist.

The patient had no significant family history, and her past medical history included right nephrolithiasis, pneumonia, and pelvic inflammatory disease (PID) uterine infection. She had no history of pulmonary tuberculosis (PTB). She did not engage in smoking or drinking.

On examination, pulse and blood pressure could not be recorded on the upper extremities, but pulses were palpable in the lower extremities. A silent right carotid area and the presence of bruits in the left carotid area were noted. However, pulsations of the aorta, femoral artery, and popliteal artery were normal.

Initial laboratory tests revealed a white blood cell count (WBC) of 10,500 with differential counts: neutrophils (N) 50%, lymphocytes (L) 38%, eosinophils (E) 3%, monocytes (M) 8%, and basophils (B) 1%. Hemoglobin (Hb) was 10.0 g/dL, and random blood sugar (RBS) was 95 mg/dL. Venereal Disease Research Laboratory (VDRL) test results were non-reactive. Due to suspicion of Takayasu arteritis, the patient was referred to a tertiary care center for further management.

Computed Tomography (CT) angiography of the aorta and its branches was carried out. CT angiography of the neck revealed diffuse symmetrical circumferential arterial thickening of the ascending aorta, aortic arch, and their branches, with significant luminal narrowing, consistent with Takayasu arteritis (figure no.1). However, the brain CTA showed normal findings (figure no. 2). Her laboratory findings are summarized in Table 1. The patient was prescribed a combination of medications to manage her condition while awaiting surgery. The treatment regimen included Prednisolone 40 mg/day orally; aspirin 75 mg/day, and pantoprazole 40 mg/day.



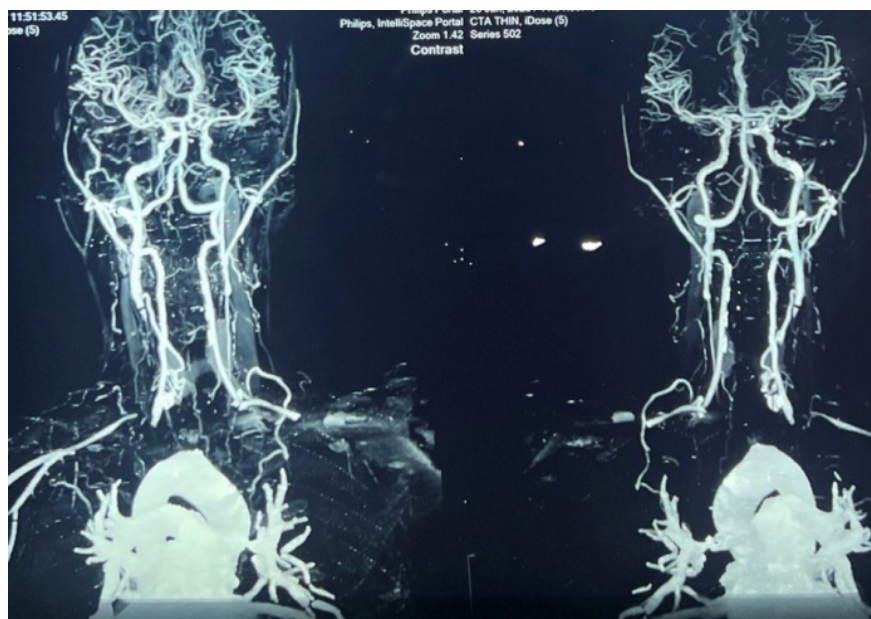


Figure 1:- Computed Tomography (CT) angiography of the aorta and its branches showing diffuse symmetrical circumferential arterial thickening of the ascending aorta, aortic arch, and their branches, with significant luminal narrowing, consistent with Takayasu arteritis.

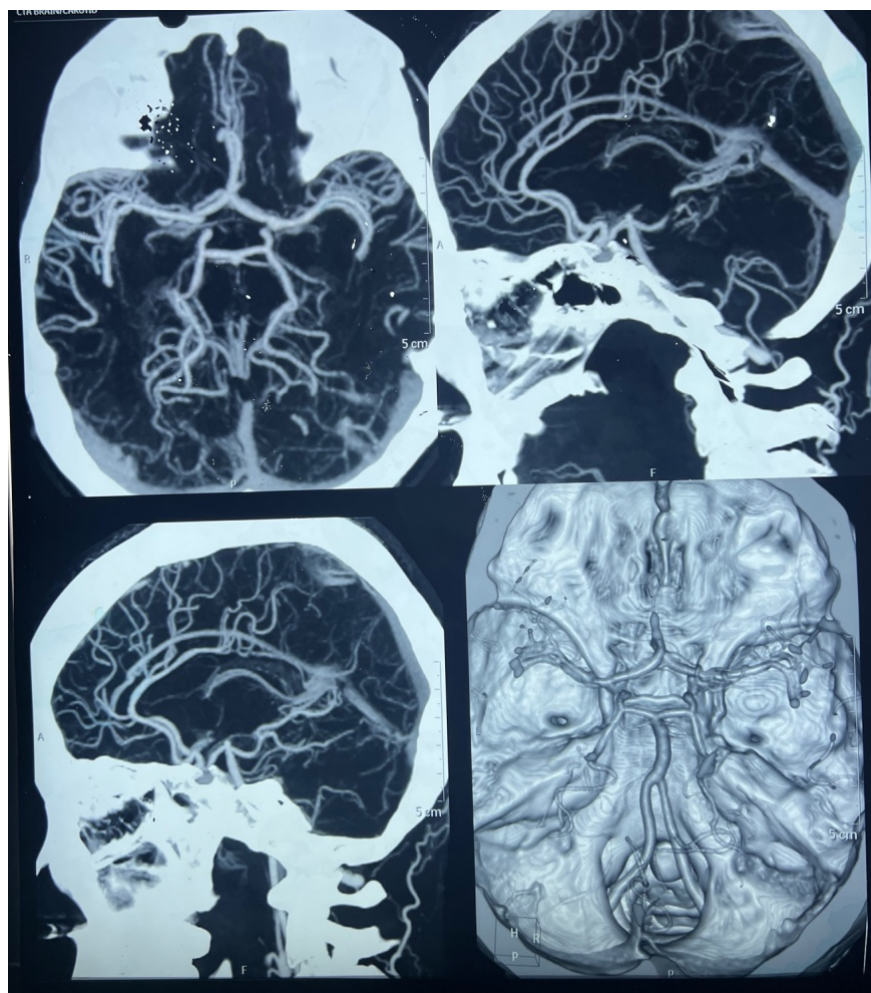


Figure 2:- Computed Tomography (CT) angiography of brain showing normal circle of Willis.

Test	Result	Normal Range
White Blood Cell Count	7,000/mm ³	4,500 - 11,000/mm ³
Neutrophils	47%	40 - 60%
Lymphocytes	48%	20 - 40%
Eosinophils	2%	0 - 6%
Monocytes	3%	2 - 10%
Basophils	0%	0 - 1%
Hemoglobin	11.3 g/dL	12 - 15.5 g/dL
Red Blood Cell Count	4.1 million/mm ³	4.2 - 5.4 million/mm ³
Platelet Count	2,22,000/mm ³	150,000 - 450,000/mm ³
Erythrocyte Sedimentation Rate (ESR)	14 mm/hour	0 - 15 mm/hour
Random Blood Sugar (RBS)	154 mg/dL	70 - 140 mg/dL
Urea	15 mg/dL	10 - 50 mg/dL
Creatinine	0.8 mg/dL	0.6 - 1.2 mg/dL
Sodium (Na)	138 mEq/L	135 - 145 mEq/L
Potassium (K)	3.29 mEq/L	3.5 - 5.0 mEq/L
C-Reactive Protein (CRP)	<1.00 mg/L	<3.0 mg/L

Test	Result	Normal Range
Antinuclear Antibody (ANA)	Negative (<5 mg/L)	Negative
Thyroid-Stimulating Hormone (TSH)	1.34 mIU/L	0.4 - 4.0 mIU/L
Free Triiodothyronine (fT3)	3.98 pg/mL	2.0 - 4.4 pg/mL
Free Thyroxine (fT4)	1.34 ng/dL	0.8 - 1.8 ng/dL

Table no. 1:- Summary of her laboratory Findings

Discussion:-

Takayasu arteritis is presently classified as systemic granulomatous large-vessel vasculitis according to the Chapel Hill Consensus Conference 2012³. This condition typically impacts young to middle-aged individuals of Asian descent and primarily affects large blood vessels such as the aorta and its main branches¹. Our patient, like many others, is a young female who exhibits the predominant occurrence of Takayasu arteritis in this demographic. The clinical manifestation of this disease can vary greatly and may resemble other disorders, thus posing diagnostic difficulties.

The diagnosis of Takayasu arteritis can be challenging due to the wide range of clinical presentations, particularly in its early stages. In around 84-96% of patients, characteristic symptoms such as diminished or absent pulses, limb claudication, and differences in blood pressure are observed^{4,5}. Vascular bruits are frequently found in 80-94% of individuals, often impacting multiple regions, particularly the carotid arteries, subclavian arteries, and abdominal vessels^{4,6,7}. The aorta can be affected throughout its entire extent, and while any of its branches can be afflicted, the subclavian and common carotid arteries are the most commonly involved^{5,7-9}.

In this case, the patient presented with a constellation of symptoms that were indicative of vascular involvement. The initial complaints of headache and vision problems aggravated in crowded areas and associated with nausea, raised suspicion of involvement of the carotid arteries and cerebral circulation. The gradual diminishment of vision with exertion, which improved with rest and head bending, is consistent with the phenomenon of "ocular ischemic syndrome" often seen in Takayasu arteritis.

Furthermore, the patient reported recurrent dizziness, falls, and easy fatigability, particularly in the upper extremities. These symptoms can be attributed to subclavian artery involvement and impaired blood flow to the arms. The difficulty in obtaining blood pressure measurements and absence of pulses in the upper extremities, along with the presence of bruits in the left carotid area, further support the suspicion of large vessel involvement. The normal pulsations observed in the aorta, femoral artery, and popliteal artery suggest sparing of the distal vessels in this case.

Preferably, early diagnosis of Takayasu arteritis is essential during the prestenotic phase. The diagnosis primarily relies on clinical features and imaging findings. Elevated levels of acute phase reactants like erythrocyte sedimentation rate (ESR) and C-reactive protein (CRP) may be observed, but these tests do not consistently indicate the severity of the disease and can appear normal even when the disease is active⁷. In our particular case, the ESR level was within the normal range. Over the last decade, significant progress has been made in the field of medical imaging, leading to a better understanding of how large vessel vasculitides affect the vascular system. These advancements have also become increasingly vital in clinical management^{10,11}. Various imaging techniques, such as high-resolution ultrasound (US), magnetic resonance imaging (MRI), magnetic resonance angiography (MRA), CT angiography (CTA), and positron emission tomography (PET), have been investigated in individuals diagnosed with Takayasu arteritis. The existing small and typically retrospective studies suggest that, although there is no single modality that provides all the required information, they might have distinct and complementary roles in patient care^{12,13}.

Early initiation of medical treatments is generally recommended to minimize vascular injuries, particularly the combination of corticosteroids and immunosuppressive agents². Corticosteroids remain the primary

treatment option and have shown effectiveness in 20-75% of patients with "active aortitis"^{14,15}. Steroid therapy often leads to a positive response in the erythrocyte sedimentation rate (ESR), which serves as a reliable indicator of disease activity¹⁶. Anti-platelet therapy is commonly recommended to prevent further ischemic events³. In cases of severe and symptomatic aortic branch arterial disease, patients should be considered for either endovascular procedures or surgery^{9,17}.

In our case, the patient exhibited signs of depression, which is not uncommon in chronic illnesses. The presence of depression further underscores the importance of providing comprehensive care, including psychological support and addressing the patient's emotional well-being. While our patient responded well to medical management, it is essential to acknowledge the limitations of this case report. The follow-up period was relatively short, and long-term outcomes were not evaluated. Furthermore, due to resource constraints, some investigations and laboratory reports were not available, which may have provided additional insights into the disease course.

Conclusion:-

In conclusion, Takayasu arteritis presents with a heterogeneous clinical profile, involving multiple organ systems. The non-specific nature of symptoms and the potential overlap with other conditions pose challenges for diagnosis. It is crucial for clinicians to maintain a high index of suspicion, particularly in young females presenting with symptoms such as headache, vision problems, dizziness, and upper extremity fatigue. Early recognition, appropriate diagnostic evaluation, and timely initiation of treatment are paramount to improve patient outcomes and prevent complications associated with Takayasu arteritis. Further research is needed to enhance our understanding of the disease and develop more effective diagnostic and treatment strategies.

REFERENCES:-

1. De Souza AWS, de Carvalho JF. Diagnostic and classification criteria of Takayasu arteritis. *J Autoimmun* . 2014;48-49:79-83. doi:10.1016/J.JAUT.2014.01.012
2. Mason JC. Takayasu arteritis—advances in diagnosis and management. *Nat Rev Rheumatol* . 2010;6(7):406-415. doi:10.1038/NRRHEUM.2010.82
3. Nakagomi D, Jayne D. Outcome assessment in Takayasu arteritis. *Rheumatology* . 2016;55(7):1159-1171. doi:10.1093/RHEUMATOLOGY/KEV366
4. Lupi-Herrera E, Sánchez-Torres G, Marcushamer J, Mispireta J, Horwitz S, Espino Vela J. Takayasu's arteritis. Clinical study of 107 cases. *Am Heart J* . 1977;93(1):94-103. doi:10.1016/S0002-8703(77)80178-6
5. Subramanyan R, Joy J, Balakrishnan KG. Natural history of aortoarteritis (Takayasu's disease). *Circulation* . 1989;80(3):429-437. doi:10.1161/01.CIR.80.3.429
6. Hall S, Barr W, Lie JT, Stanson AW, Kazmier FJ, Hunder GG. Takayasu arteritis. A study of 32 North American patients. *Medicine (Baltimore)* . 1985;64(2):89-99. doi:10.1097/00005792-198503000-00002
7. Kerr GS, Hallahan CW, Giordano J, et al. Takayasu arteritis. *Ann Intern Med* . 1994;120(11):919-929. doi:10.7326/0003-4819-120-11-199406010-00004
8. Jain S, Kumari S, Ganguly NK, Sharma BK. Current status of Takayasu arteritis in India. *Int J Cardiol* . 1996;54 Suppl(S2):S111-S116. doi:10.1016/S0167-5273(96)88780-8
9. Mwiipatayi BP, Jeffery PC, Beningfield SJ, et al. Takayasu arteritis: clinical features and management: report of 272 cases. *ANZ J Surg* . 2005;75(3):110-117. doi:10.1111/J.1445-2197.2005.03312.X
10. Andrews J, Mason JC. Takayasu's arteritis—recent advances in imaging offer promise. *Rheumatology (Oxford)* . 2007;46(1):6-15. doi:10.1093/RHEUMATOLOGY/KEL323
11. Blockmans D, Bley T, Schmidt W. Imaging for large-vessel vasculitis. *Curr Opin Rheumatol* . 2009;21(1):19-28. doi:10.1097/BOR.0B013E32831CEC7B

12. Meller J, Strutz F, Siefker U, et al. Early diagnosis and follow-up of aortitis with [(18)F]FDG PET and MRI. *Eur J Nucl Med Mol Imaging* . 2003;30(5):730-736. doi:10.1007/S00259-003-1144-Y
13. Andrews J, Al-Nahhas A, Pennell DJ, et al. Non-invasive imaging in the diagnosis and management of Takayasu's arteritis. *Ann Rheum Dis* . 2004;63(8):995-1000. doi:10.1136/ARD.2003.015701
14. Ito I. Medical treatment of Takayasu arteritis. *Heart Vessels Suppl* . 1992;7(1 Supplement):133-137. doi:10.1007/BF01744559
15. Hoffman GS. Takayasu arteritis: lessons from the American National Institutes of Health experience. *Int J Cardiol* . 1996;54 Suppl(S2):S99-S102. doi:10.1016/S0167-5273(96)88778-X
16. Hoffman GS, Ahmed AE. Surrogate markers of disease activity in patients with Takayasu arteritis. A preliminary report from The International Network for the Study of the Systemic Vasculitides (INSSYS). *Int J Cardiol* . 1998;66 Suppl 1(SUPPL. 1). doi:10.1016/S0167-5273(98)00181-8
17. Noel N, Butel N, Le Hoang P, et al. Small vessel involvement in Takayasu's arteritis. *Autoimmun Rev* . 2013;12(3):355-362. doi:10.1016/J.AUTREV.2012.05.010

Hosted file

figures.docx available at <https://authorea.com/users/639447/articles/654752-a-case-of-takayasu-arteritis-in-a-young-female-clinical-features-diagnostic-challenges-and-treatment-approach>

Hosted file

tables.docx available at <https://authorea.com/users/639447/articles/654752-a-case-of-takayasu-arteritis-in-a-young-female-clinical-features-diagnostic-challenges-and-treatment-approach>