

Hemifacial spasm and blepharospasm caused by vertebral artery dolichoectasia

Entela Basha¹, Gentian Vyshka², Eris Ranxha³, and Artur Xhumari¹

¹“Mother Teresa” University Medical Center, Tirana, Albania

²Faculty of Medicine, University of Medicine

³University Hospital Centre “Mother Teresa”

March 28, 2024

Hemifacial spasm and blepharospasm caused by vertebral artery dolichoectasia

Entela Basha ¹, Gentian Vyshka^{2*}, Eris Ranxha ¹, Artur Xhumari³

1. Neurovascular Service, “Mother Teresa” University Medical Center, Tirana, Albania
2. Biomedical and Experimental Department, University of Medicine in Tirana, Albania
3. Service of Neurosurgery, “Mother Teresa” University Medical Center, Tirana, Albania

***Corresponding author at:**gvyshka@gmail.com

ABSTRACT

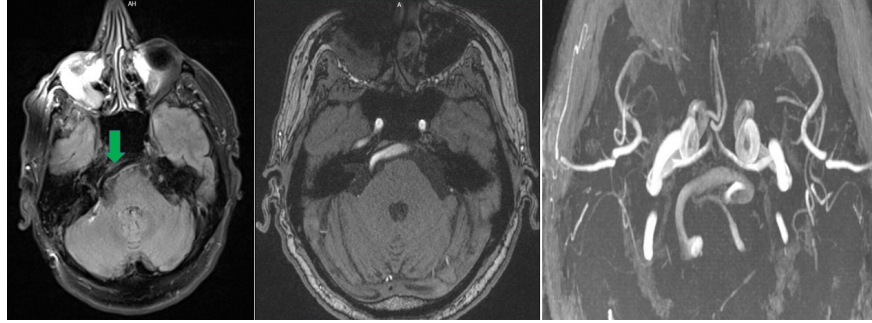
Hemifacial spasm and blepharospasm are crippling medical conditions that severely affect the quality of life of patients. Among differential diagnosis, the ectasia of vertebro-basilar vessels should be taken into account, and treated accordingly.

Authors report the case of a 60-years old male with a two-year history of involuntary intermittent twitching of the right eye and right side of the upper lip. MRI of the brain suggested a dolichoectasia of the vertebral artery. The condition was almost refractory to drugs and the patient was referred for neurosurgical intervention.

Keywords: *hemifacial spasm, blepharospasm, neurovascular conflict*

Hemifacial spasm and blepharospasm are subtypes of peripheral movement disorder. They are divided into primary and secondary categories based on their etiology. Primary hemifacial spasm usually follows a neurovascular conflict between the posterior circulation vessels and facial nerve root, while common secondary causes are the Bell’s palsy, traumatic injury of the facial nerve, demyelination, and stroke [1, 2].

A 60 years old Albanian man reported a two-year history of involuntary intermittent twitching of the right eye and right side of the upper lip that came to his attention only recently due to increased frequency. The patient did not report any other medical illnesses, nor a positive family history of involuntary movements. When asked, he denied contractions in other body parts. Unilateral involuntary contractions affecting his right orbicularis oculi and right orbicularis oris were noted during neurological examination. Spasms were isolated in these two muscles and no other objective sign was found.



Routine biochemical tests and cell blood count were normal. Magnetic Resonance Imaging showed the neurovascular conflict between the right facial nerve and right dolichoectasia of the vertebral artery (Figure 1). The neurosurgical team recommended microvascular decompression surgery of the facial nerve as a definitive treatment.

Figure 1 (composed): *Left and middle inset : axial MRI images, plain and contrast-phase (angio) showing the dilated, ectatic right vertebral artery in close contact with brainstem structures. Right inset: angio-MRI imaging of the vessel tortuosity, right vertebral artery.*

The patient refused it and preferred pharmacological treatment. We decided to start the treatment with Clonazepam 2 mg per day. The patient came after several months without any clinical improvement. During these follow-up visits, the neurological examination remained unchanged. Treatment with Baclofen 40 mg per day was started, without any improvement. The patient decided to undergo surgery after unsuccessful pharmacological treatment. The spasms resolved the next postoperative day, without recurrence after a one-year follow-up.

Dolichoectasia of the vertebro-basilar system is a normal anatomic variant, where the arteries are enlarged and tortuous. It is usually not associated with neurological complications. Some cases have reported manifestations of dolichoectasia of vertebro-basilar system with hydrocephaly, bulbar compression, and vestibulocochlear symptoms [3]. In most cases, primary hemifacial spasms and blepharospasm relate to a neurovascular conflict of the anterior inferior cerebellar artery and posterior inferior cerebellar artery, while our patient's symptoms were caused by dolichoectasia of the vertebral artery. Herewith we emphasize the importance of surgical treatment as a permanent solution to this condition.

References

1. Campos-Benitez M, Kaufmann AM. Neurovascular compression findings in hemifacial spasm. J Neurosurg. 2008 Sep;109(3):416-20.
2. Yaltho TC, Jankovic J. The many faces of hemifacial spasm: differential diagnosis of unilateral facial spasms. Mov Disord. 2011 Aug 1;26(9):1582-92.
3. Huh G, Bae YJ, Woo HJ, Park JH, Koo JW, Song JJ. Vestibulocochlear Symptoms Caused by Vertebrobasilar Dolichoectasia. Clin Exp Otorhinolaryngol. 2020 May;13(2):123-132.

Conflict of interest

Nothing to declare

Acknowledgements

None

Informed Consent

Obtained

Authors' contributions

EB, GV: manuscript writing, data collection, literature review. ER, AX: manuscript drafting, data collection and patient follow-up. All authors approved the submitted version.

KEY CLINICAL MESSAGE

Hemifacial spasm and blepharospasm are crippling medical conditions that severely affect the quality of life of patients. Among differential diagnosis, the ectasia of vertebro-basilar vessels should be taken into account, and treated accordingly. Neurosurgery of the vascular conflict is a definitive treating option, while pharmacological treatment might offer some temporary relief.

