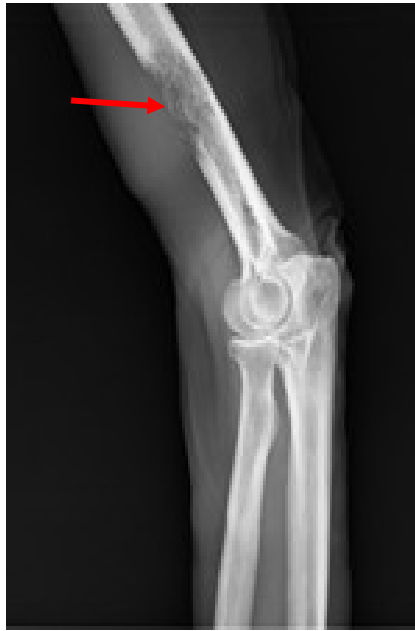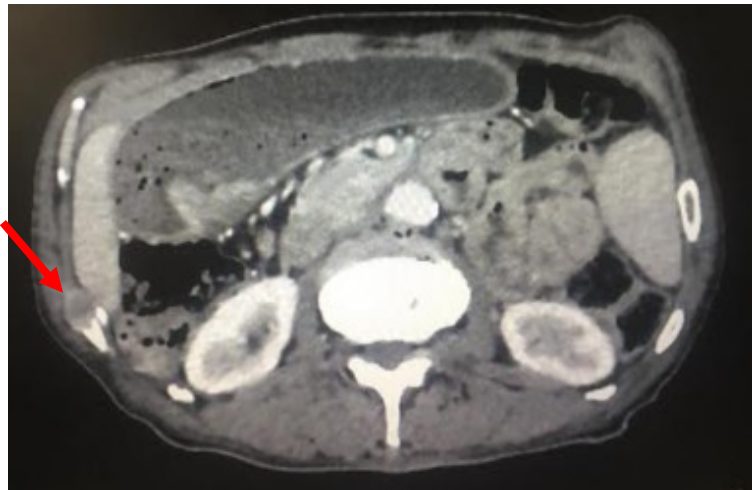
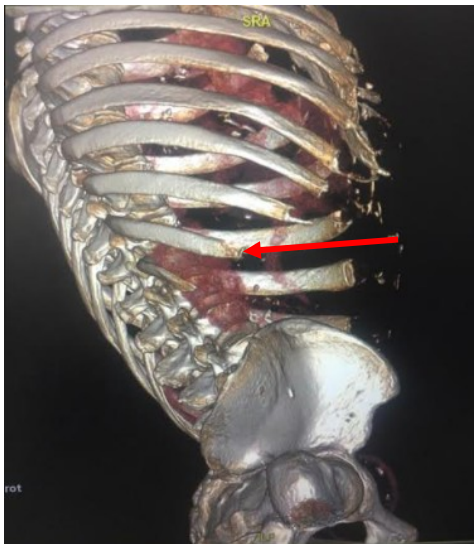


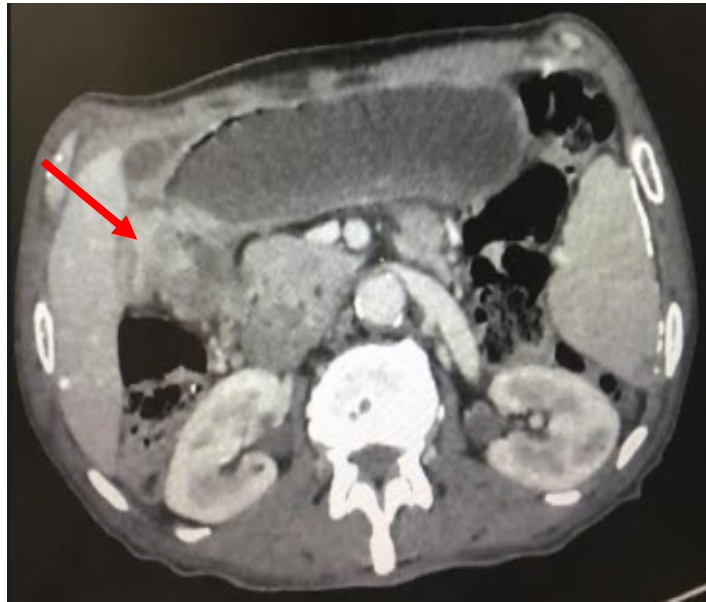## Figures



**Figure 1:** Pathologic fracture on a lytic lesion (arrow), X-ray of the right humerus



**Figure 2:** Lytic lesion in the 11<sup>th</sup> right rib (arrows), CT scan



**Figure 3:** Gastric mass (arrow), CT scan