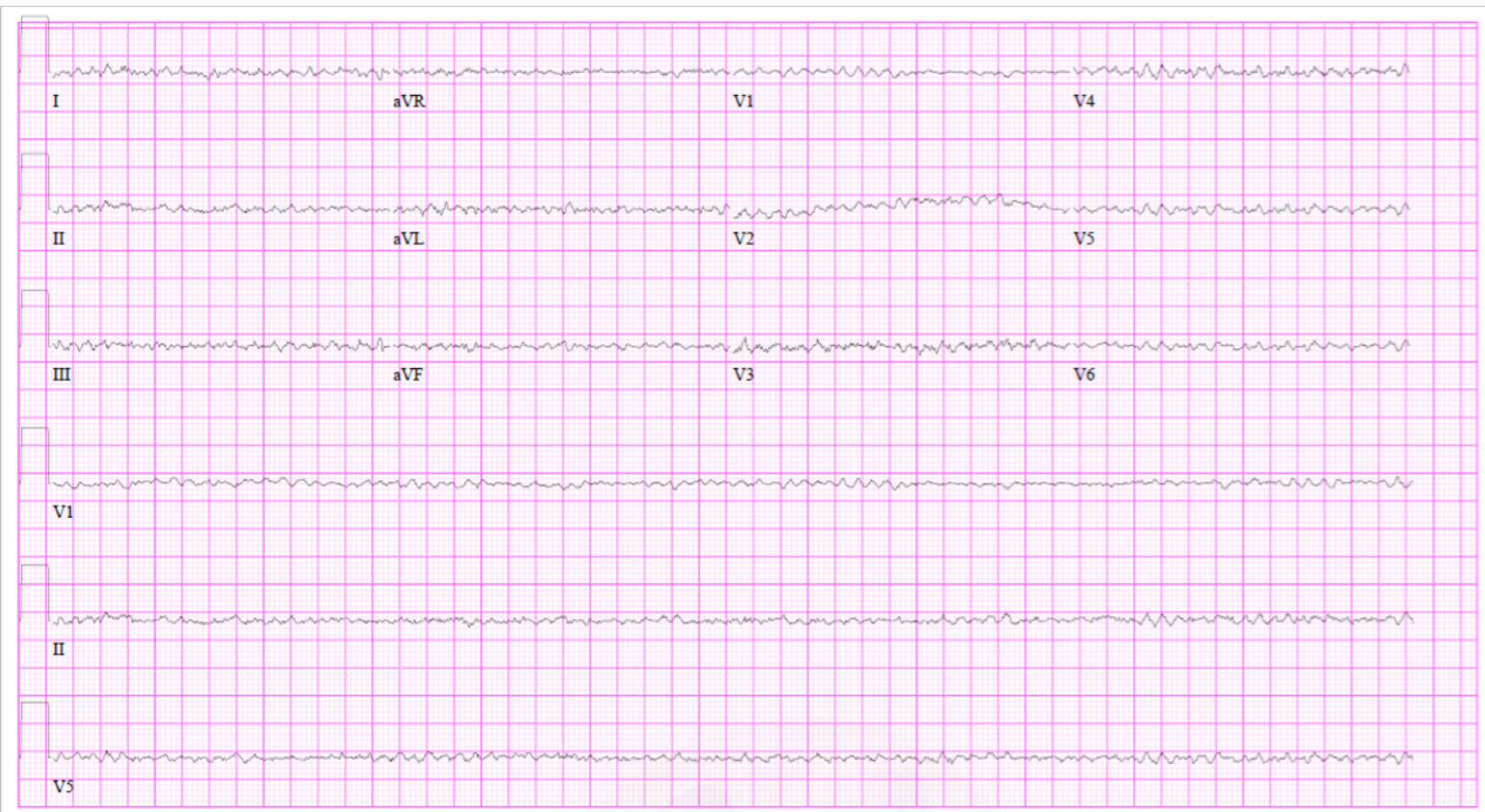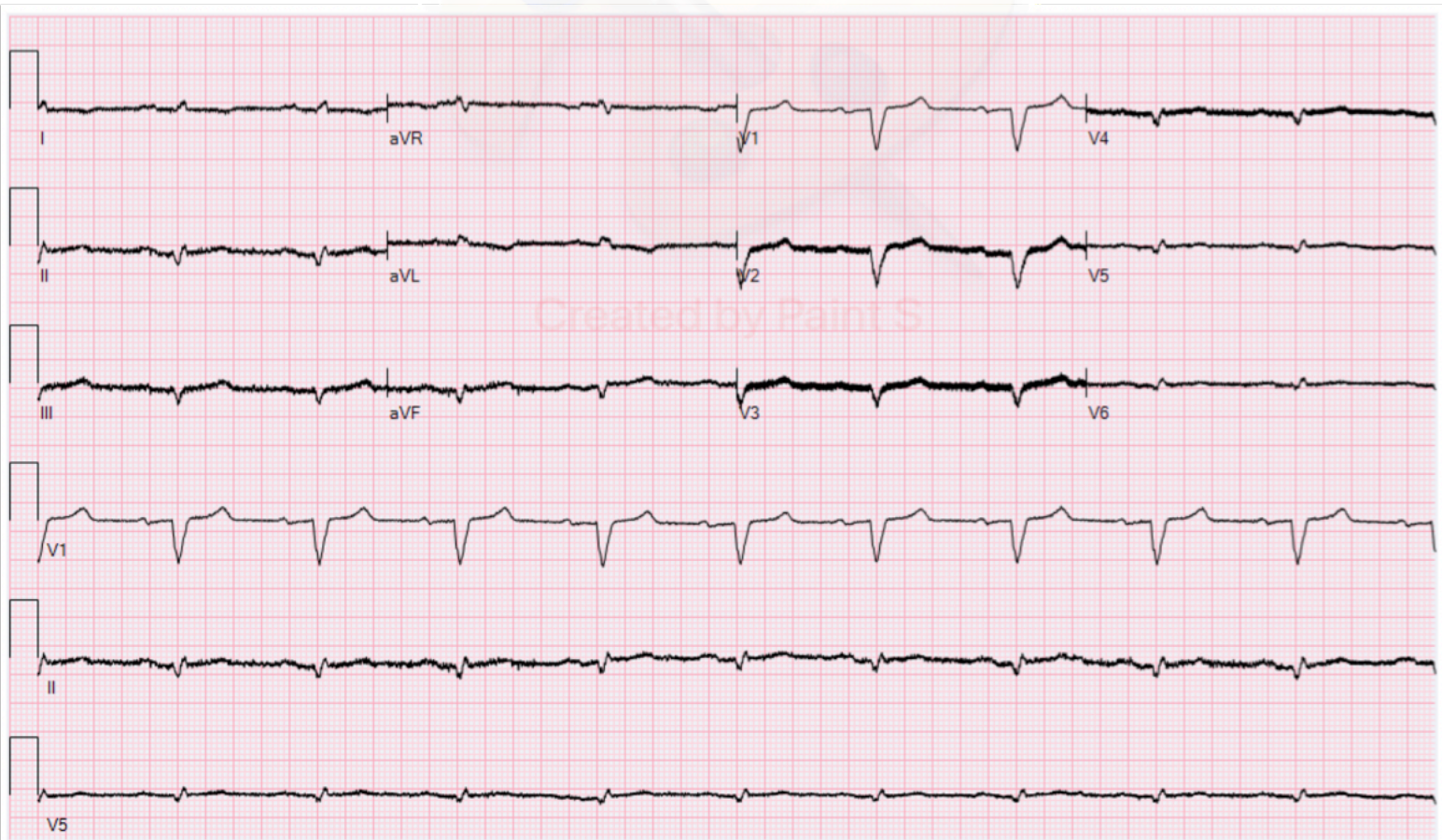


ECG 1: Initial ECG obtained on presentation to the hospital demonstrating disorganized activity.



ECG 2: Post defibrillation ECG demonstrating normal sinus rhythm.